

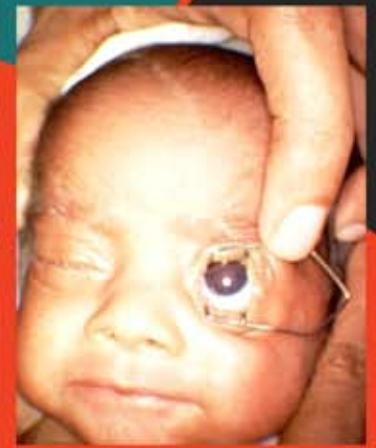
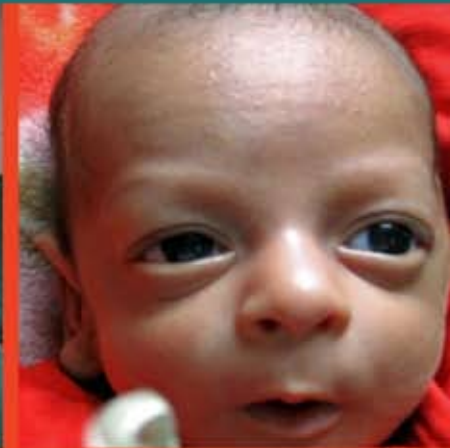
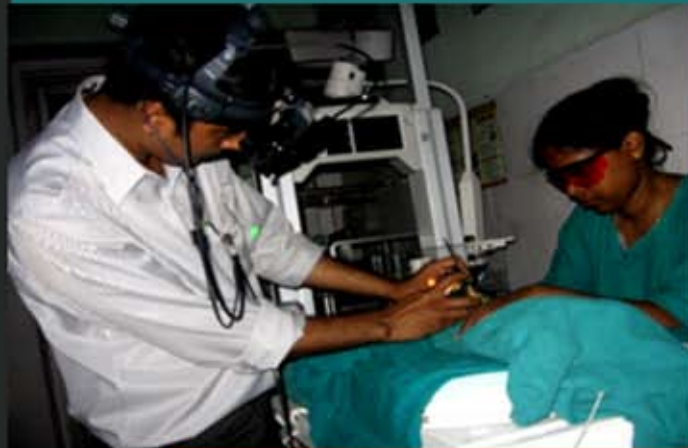RBSK

RASHTRIYA BAL SWASTHYA KARYAKRAM
राष्ट्रीय बाल स्वास्थ्य कार्यक्रम
FROM SURVIVAL TO HEALTHY SURVIVAL



GUIDELINES FOR
**UNIVERSAL EYE SCREENING
IN NEWBORNS**
INCLUDING RETINOPATHY OF PREMATURITY



RASHTRIYA BAL SWASTHYA KARYAKRAM
Ministry of Health & Family Welfare
Government of India

June 2017



सत्यमेव जयते



GUIDELINES FOR
UNIVERSAL EYE SCREENING
IN NEWBORNS
INCLUDING RETINOPATHY OF PREMATURITY

RASHTRIYA BAL SWASTHYA KARYAKRAM
Ministry of Health & Family Welfare
Government of India

June 2017



सी.के.मिश्रा
सचिव
C.K.Mishra
Secretary



भारत सरकार
स्वास्थ्य एवं परिवार कल्याण विभाग
स्वास्थ्य एवं परिवार कल्याण मंत्रालय
Government of India
Department of Health and Family Welfare
Ministry of Health & Family Welfare

MESSAGE



The Ministry of Health & Family Welfare, Government of India, under the National Health Mission launched the Rashtriya Bal Swasthya Karyakram (RBSK), an innovative and ambitious initiative, which envisages Child Health Screening and Early Intervention Services. The main focus of the RBSK program is to improve the quality of life of our children from the time of birth till 18 years through timely screening and early management of 4 'D's namely Defects at birth, Development delays including disability, childhood Deficiencies and Diseases.

To provide a healthy start to our newborns, RBSK screening begins at birth at delivery points through comprehensive screening of all newborns for various defects including eye and vision related problems. Some of these problems are present at birth like congenital cataract and some may present later like Retinopathy of prematurity which is found especially in preterm children and if missed, can lead to complete blindness.

Early Newborn Eye examination is an integral part of RBSK comprehensive screening which would prevent childhood blindness and reduce visual and scholastic disabilities among children.

Universal newborn eye screening at delivery points and at SNCUs provides a unique opportunity to identify and manage significant eye diseases in babies who would otherwise appear healthy to their parents.

I wish that State and UTs would benefit from the '**Guidelines for Universal Eye Screening in Newborns including Retinopathy of Prematurity**' and in supporting our future generation by providing them with disease free eyes and good quality vision to help them in their overall growth including scholastic achievement.


(C.K. Mishra)



Arun Kumar Panda

Additional Secretary &
Mission Director, NHM

Tele : 23063155, Fax : 23063156

E-mail : asmd-mohfw@nic.in



सत्यमेव जयते

भारत सरकार

स्वास्थ्य एवं परिवार कल्याण मंत्रालय

स्वास्थ्य एवं परिवार कल्याण विभाग

निर्माण भवन, नई दिल्ली-110011

GOVERNMENT OF INDIA

MINISTRY OF HEALTH & FAMILY WELFARE

DEPARTMENT OF HEALTH & FAMILY WELFARE

NIRMAN BHAVAN, NEW DELHI - 110011

28th June, 2017

Message



Rashtriya Bal Swasthya Karyakram is an innovative initiative of Ministry of Health and Family Welfare to promote early screening, evaluation and management of thirty prevalent health conditions in children from birth to 18 years of age. To ensure healthy survival for every child, screening is done for Defects at birth, Developmental Delay, Childhood Diseases and Deficiencies at multiple levels such as Delivery point, Routine home visit by ASHA, Anganwadi Centre, Government and Govt. aided Schools followed by assured medical and surgical treatment of these conditions.

Screening at Delivery Point is crucial for early identification of birth defect which may either result in death or disability having lifelong impact.

Universal newborn eye screening provides an opportunity to identify and manage the eye conditions like congenital cataract, congenital glaucoma which restrict the child's brain from getting visual inputs from the surroundings to restore the vision. The real challenge is the timing of intervention as these conditions provide a small critical period for successful intervention to restore the vision. Once this window of opportunity is lost, the child loses the vision for the rest of life irrespective of the quality of management one may undertake. Retinopathy of Prematurity (ROP) is also such condition and is emerging as one of the important causes of preventable childhood blindness in India.

I am sure that State and UTs would benefit from the '**Guidelines for Universal Eye Screening in Newborns including Retinopathy of Prematurity**'. I urge all the States/UTs to seriously take the initiative of early newborn eye screening and prevent children from becoming blind.


(Dr. Arun K Panda)

Healthy Village, Healthy Nation





LAV AGARWAL, I.A.S.
Joint Secretary

Tel. : 011-23061195
T/Fax : 011-23061842
E-mail : alav@ias.nic.in



भारत सरकार
स्वास्थ्य एवं परिवार कल्याण मंत्रालय
निर्माण भवन, नई दिल्ली - 110011
Government of India
Ministry of Health & Family Welfare
Nirman Bhavan, New Delhi - 110011

Dated 23/06/2017

PROLOGUE



The ability to form a focused image with both the eyes is one of the most important inputs for the development of the brain and the cognitive functions in an infant especially during the first two years of life.

Any visual impairment or low vision in the newborn infant not only affects his/her development but is a social economic burden on the child's family, society and the nation. Many of the Eye Diseases causing blindness in childhood can be treated if detected early by universal screening of the newborns in labor rooms and special newborn care units (SNCUs).

Retinopathy of Prematurity (ROP) is an eye disease occurring in prematurely born babies. It is a problem that affects the retina, wherein, unwanted blood vessels grow on the retina of the newborn. These blood vessels can lead to vitreous traction, retinal detachment and blindness. Therefore ROP needs to be detected in high risk infants and treated at the earliest. Moreover, infants with ROP are considered to be at higher risk for developing eye problems like Myopia, Glaucoma and Squint later in life. With the improving quality of newborn care, more and more premature and low birth weight babies are being saved, but putting them at risk of developing ROP and if undetected and untreated, making them irreversibly blind for life. Various studies from India have reported ROP in 20-25% of the screened neonates. Given the huge birth cohort in the country, this may translate to substantial numbers.

Keeping in view, the severity of the problem, the Guidelines for Universal Eye Screening including ROP in Newborns have been developed. These guidelines stress on comprehensive eye screening of the newborn with particular focus on ROP screening in high risk babies.

I hope that the valuable information and procedures given in this publication will guide the program managers, eye surgeons, medical officers and health personnel in labor rooms & SNCUs in establishing, strengthening and maintaining high quality eye care services in infants.

I appreciate the efforts and contribution of the various governmental and non-governmental organizations in producing this extremely useful document.

Lav Agarwal
Joint Secretary
NPCB



Manoj Jhalani
Joint Secretary & CVO
Telefax : 23063687
E-mail : manoj.jhalani@nic.in



भारत सरकार
स्वास्थ्य एवं परिवार कल्याण मंत्रालय
निर्माण भवन, नई दिल्ली-110011

GOVERNMENT OF INDIA
MINISTRY OF HEALTH & FAMILY WELFARE
NIRMAN BHAVAN, NEW DELHI - 110011



PREAMBLE

The critical period of brain development happens in the first two years of life. Visual perception helps the child to explore the surroundings and provide vital inputs to assist in the social, motor and cognitive development of the child especially in initial two years of life.

Eyes and vision play a critical role in enabling the child to see and learn. From birth, babies begin by exploring and scanning the world around them with their eyes, even before they learn to reach and hold an object.

40 per cent of the human brain is devoted to processing visual information to understand the world around and interact with it appropriately. Children born with structural eye defects like cataract or glaucoma are deprived of the visual information for the brain to process and learn. The difficulty being that neither the parents nor the care giver are aware of this in the initial stages as these children appears normal at birth. By the time the eye problem is identified, the brain has already lost a lot of valuable inputs required for its development.

Premature babies have many obstacles to overcome in the beginning of their lives. One of those obstacles is eye and vision development. Due to their vulnerability as preterm they develop a disease called Retinopathy of Prematurity which if not treated timely may lead to permanent blindness.

A comprehensive eye screening for all newborns at the time of birth, including both preterm and term can help in avoiding serious vision problems including blindness.

'Guidelines for Universal Eye Screening in Newborns including Retinopathy of Prematurity' can be used to facilitate the process of early identification of eye problems in newborns and their timely management. This would help in preservation of their visual function and improvement of scholastic achievements.

I am hopeful that States/UTs would use this technical and operational guideline to screen newborns for eye related disorders so that early management can be initiated to prevent childhood blindness and vision impairment.

(Manoj Jhalani)

वन्दना गुरनानी, मा.प्र.से.
संयुक्त सचिव

VANDANA GURNANI, I.A.S.
JOINT SECRETARY
Tel. : 011-23061706
E-mail : vandana.g@ias.nic.in



भारत सरकार
स्वास्थ्य एवं परिवार कल्याण मंत्रालय
निर्माण भवन, नई दिल्ली - 110011
Government of India
Ministry of Health & Family Welfare
Nirman Bhavan, New Delhi - 110011

FOREWORD



Rashtriya Bal Swasthya Karyakram is a National Programme aimed at improving the quality of life of children from Birth to 18 years through early screening and management of selected health conditions.

Eyes are one of the most important sensory organs for a newborn. They provide continuous visual inputs to the brain of a growing child which enables them to see and learn. Equal inputs from both eyes are essential for developing cognitive skills of a newborn. Providing a clear focused image to the brain is essential for proper understanding of his or her surroundings.

Structural defects like congenital cataract, congenital glaucoma or retinal problems like Retinopathy of Prematurity are a part of the selected health conditions under RBSK. If not addressed timely, these conditions can lead to blindness or severe visual impairment.

Premature infants weighing less than 2000 grams or those born before 34 weeks of gestation are at risk of developing Retinopathy of Prematurity (ROP). Studies from India have reported an incidence of ROP in 20-22% of the screened preterm newborns. Given the huge birth cohort in the country, this would translate to substantial numbers.

In eye related disorders timing is one of the significant considerations that make treatment successful. Some eye conditions can advance very quickly and delayed treatments are often not effective in such cases. Hence early Eye screening of all newborns is essential to ensure early intervention for better vision and cognitive development.

'Guidelines for Universal Eye Screening in Newborns including Retinopathy of Prematurity' are to emphasise on the importance of universal eye screening in newborns including ROP screening among preterm babies under RBSK.

I am hopeful that this guideline would be used appropriately to identify eye related disorders in newborns so that timely management can be initiated to ensure healthy, disease free life for children in accordance with the philosophy of RBSK.

Vandana Gurnani



Dr. Ajay Khera

M.B.B.S., D.G.O., M.D. (Public Health)
Deputy Commissioner & Incharge
(Child & Adolescent Health)
Telefax : 23061281
E-mail : dcmch-mohfw@nic.in
ajaykheramch@gmail.com



भारत सरकार
स्वास्थ्य एवं परिवार कल्याण मंत्रालय
निर्माण भवन, नई दिल्ली-110011
GOVERNMENT OF INDIA
MINISTRY OF HEALTH & FAMILY WELFARE
NIRMAN BHAVAN, NEW DELHI - 110011



PREFACE

It is estimated that currently there are approximately 270,000 blind children in India. The major causes of blindness in children include cataract, Retinopathy Of Prematurity (ROP), and Vitamin A deficiency. Approximately half of all the childhood blindness' can be avoided or treated.

There are many causes of vision loss. Some cause more severe loss than others. One of the most common conditions is ROP, an eye problem that occurs mainly in babies born before 31 weeks of pregnancy. About 90 percent of all infants with ROP are in the milder category and do not need treatment. However, infants with more severe disease can develop impaired vision or even blindness

In India the incidence of ROP has been reported at 24–47% among high risk preterm infants. The improved survival of preterm and small-for-date neonates in our country, especially after the operationalisation of NICUs and SNCUs, has led to an increase in the incidence of ROP in infants.

Timing is one of the important factors that make the treatment successful in ROP, because the disease can advance very quickly and delayed treatment often reduces the chances of success. If we are able to identify the eye disorders right at birth and/or during the stay of High Risk Babies at SNCUs/NICUs we are utilising the window of opportunity to treat the disorder at the earliest and thus preventing developmental delays in these children.

The current manual for health care functionaries has got two components: Technical component that deals with primary management of all disorders in Newborn and ROP screening, interpretation & management of 'at risk new-borns' and Operational component on implementation of Universal Vision and ROP screening and Management.

We hope this manual will be a valuable reference for the Paediatrician/Medical officers of SNCU, SNCU Staff Nurse, Optometrist of the DEIC, Ophthalmologist of District Hospital/ Private Hospital to identify and manage eye related disorders in newborns and also for the Programme managers at the State, District & Block Levels.


(Dr. Ajay Khera)
20/08/17

ACKNOWLEDGEMENT

Guidelines for Universal Eye Screening in newborns including Retinopathy Of Prematurity (ROP) is a unique document which comprehensively focuses on identification of all the treatable conditions of the ocular system. Some are present at birth for e.g., microphthalmos, anophthalmos, corneal opacity, congenital cataract, congenital glaucoma and some are acquired during the neonatal period for e.g., Retinopathy Of Prematurity, Ophthalmia neonatorum.

ROP affects low-birth-weight premature infants and can lead to blindness; the incidence of ROP has increased in our country, as smaller and younger babies are surviving through initiatives like SNCU.

This document is to guide and support medical officers, paediatricians, optometrists and ophthalmologists in the country towards timely identification, primary management and referral of all treatable eye disorders including ROP in New-born and has been prepared with valuable inputs from experts across the country.

We would like to acknowledge the support of various experts and contributors who have given their inputs which immensely helped to give this manual a final shape.

I wish success and pledge my unstinting support towards implementation of this initiative.

Dr. Arun Kr. Singh
National Advisor, RBSK

CONTRIBUTORS

- Dr. Mangat Dogra, PGI Chandigarh
- Dr. Pranab Das, Calcutta Medical Research Institute
- Dr. Ramesh Kekunnaya, LV Prasad Eye Institute, Hyderabad
- Dr. Clare Gilbert, Professor, London School of Hygiene and Tropical Medicine
- Dr. G.V.S. Murthy, Director, IIPH, Hyderabad
- Dr. Lea Hyvarinen, Professor, University of Dortmund & University of Helsinki
- Dr. Praveen Kumar, PGI Chandigarh
- Dr. Ashok Deorari, AIIMS, New Delhi
- Dr. Anand Vinekar, Narayana Netralaya, Bangalore
- Dr. Namita Jacob, Chetana Charitable Trust, Chennai
- Dr. Pradeep Sharma, RP Centre, AIIMS, New Delhi
- Dr. Parijat Chandra, RP Centre, AIIMS, New Delhi
- Dr. P. Vijayalakshmi, Chief- Paediatric Ophthalmology, Aravind Eye Hospital, Madurai
- Dr. Subhadra Jalali, LV Prasad Eye Institute, Hyderabad
- Dr. Suchandra Mukherjee, IPGMER, Kolkata
- Dr. Rajan Shukla, PHFI

Members of ROP committee under NPCB, MOHFW, GOI

- Prof. Atul Kumar, Chief, RP Centre, AIIMS, New Delhi & Advisor (Ophth.), GOI
- Dr. Promila Gupta, DDG (NPCB), Dte. GHS, MOHFW, GOI
- Dr. V. Rajshekhar V, Eye Surgeon & AC (NPCB), MOHFW, GOI
- Dr. Ashok K Deorari, Professor, Dept. of Pediatrics, AIIMS, New Delhi
- Dr. Harish Chellani, Professor, Dept. of Pediatrics, VMMS & Safdurjung Hospital, NewDelhi
- Dr. Praveen Vashisht, Professor Incharge, Dept. of Community Medicine, RP Centre, AIIMS, New Delhi
- Dr. Parijat Chandra, Additional Professor, RP Centre, AIIMS, New Delhi
- Dr. Rohan Chawla, Assitant Professor, RP Centre, AIIMS, New Delhi

Compiled and Edited - Dr. Arun Kumar Singh (National Advisor - RBSK)

ABOUT THE DOCUMENT

This document has been developed for various health care functionaries for the effective implementation of screening & management of eye disorders in newborn including Retinopathy Of Prematurity.

The document has got two components viz., Technical & Operational

1. **Technical Component** for Pediatrician/Medical officers of Special Newborn Care Unit (SNCU), SNCU Staff Nurse, Optometrist of the DEIC and the Ophthalmologist of District Hospital/ Private Hospital on:
 - a. **Universal Eye screening** in all newborns including referral guidelines (Pediatrician/Medical officers of SNCU, SNCU Staff Nurse, Medical officers and Staff nurse/ANM at all delivery points)
 - b. **Importance of ROP screening, Initial Steps:** preparing newborns for ROP screening, Timing of referral and significance of Aggressive Posterior Retinopathy Of Prematurity (APROP) (Pediatrician/Medical officers of SNCU, SNCU Staff Nurse, Optometrist attached to the District Early Intervention Center)
 - c. **ROP screening, interpretation and management** of “at risk newborns” (by Ophthalmologist of District Hospital/ Private Hospital)
 - d. **Ocular history: Identifying Risk factors for vision impairment** (in future) even if eye examination is normal at birth: **follow up of such children at the DEIC/District Hospital - Ophthalmology OPD, to be mentioned in the newborn discharge** (Pediatrician/Medical officers of SNCU, SNCU Staff Nurse, Optometrist attached to the District early intervention center)
2. **Operational Component** on Implementation of Universal Vision & ROP screening and management for:
 - a. State representative of RBSK, National Programme for Control of Blindness (NPCB), Child Health/ SNCU
 - b. District Chief Medical officer
 - c. District Nodal officer (RCH)
 - d. Administrative head of the District Hospital/ Medical College
 - e. Representative from NPCB
 - f. Representative from Local Ophthalmic association
 - g. DEIC Manager

“Pediatricians are the first line of defense in the newborn’s world”

*“Knowing is not enough - We must apply
Willing is not enough - We must do”*

TABLE OF CONTENTS

INTRODUCTION	1
1. Burden of Childhood Blindness	1
2. Rashtriya Bal Swasthya Karyakram (RBSK)	2
3. Target Group under Universal Eye Screening	3
GUIDELINES FOR: UNIVERSAL EYE SCREENING OF NEWBORNS	5
1. Universal Eye Examination in Newborns.....	5
2. What is Vision? How does the Eye Work?.....	5
3. Brief Overview of Eye Anatomy, Physiology and Terminology	7
4. Eye Examination	11
5. Tools Required for Newborn Eye Examination.....	12
6. Screening cum Referral Card.....	24
7. Pictorial Tool for Identification of Eye Defects.....	25
GUIDELINES FOR OPERATIONALISING RETINOPATHY OF PREMATUREITY (ROP)	27
1. Introduction.....	29
2. Classification of ROP: Location/Extent/Severity	30
3. Risk Factors for ROP.....	36
4. Screening of ROP	37
5. Management of ROP	45
6. Follow-up Examinations in SNCU/NICU	49
7. Complications of ROP	49
8. Issues, Follow up and Counselling	50
9. Other Modalities of Treatment.....	50
10. ROP Recording Form	53
11. Preventive Measures.....	54
12. Quality Improvement	55
13. Strategies for Control of Visual Loss from ROP.....	56
14. Exercise on ROP	57
INTEGRATED APPROACH TO UNIVERSAL EYE SCREENING	65

INTRODUCTION

1. BURDEN OF CHILDHOOD BLINDNESS

The major causes of blindness in children vary widely from region to region, being largely determined by socioeconomic development, and the availability of primary health care and eye care services. The prevalence of blindness in children is 6.5 (95% confidence interval 5.1-8.2) per 10,000 children based on population based studies from South India. As per current estimates there are 320,000 blind children (<16 years) in India. (Murthy *et. al. IJO.2008;56*).

Causes of severe visual impairment among children in India:

1. **Whole globe:** Congenital globe anomalies (microphthalmos, anophthalmos) and coloboma accounts for 20.7% to 25%¹
2. **Cornea:** Corneal scarring (mostly Vitamin A deficiency, infection) accounts for 11.6% to 26.4% of the childhood blindness
3. **Lens:** Cataract, uncorrected aphakia and amblyopia account for 10.9% to 12.3%
4. **Retina:** Retinal conditions, mainly ROP and hereditary retinal dystrophies account for 19.3% to 22%
5. **Optic nerve:** Optic nerve disorders account for 5-6%

The major causes of blindness in children include Cataract, Retinopathy Of Prematurity (ROP), and Vitamin A deficiency. Approximately half of all childhood blindness can be avoided or treated

Overall the commonest causes of blindness in children in India which could be diagnosed in neonatal period are as follows:

1. Congenital abnormalities of globe anophthalmos, microphthalmos and coloboma
2. Congenital clouding or Corneal opacities
3. Congenital cataract
4. Congenital glaucoma
5. Retinopathy Of Prematurity (acquired disorder in pre-term children)
6. Retinal conditions, mainly hereditary retinal dystrophies.
7. Ophthalmia neonatorum (acquired during the neonatal period)
8. Cortical visual impairment (acquired during the perinatal period)
9. Congenital anomalies of the whole eye, usually of unknown cause, but where genetic factors may play a role, for e.g., Retinoblastoma

1 • Dandona L, Gilbert CE, Rahi JS, Rao GN. Planning to reduce childhood blindness in India. *Indian J Ophthalmol* 1998;46:117-22

• Rahi JS, Sripathi S, Gilbert CE, *et al.* Childhood blindness in India: causes in 1318 blind school students in nine states. *Eye* 1995;9:545-50.

• World Health Organization. 10 Facts about blindness and visual impairment, 2012. Available from: http://www.who.int/features/facts/files/blindness/blindness_facts/en/index6.html.

10. Congenital infections acquired during pregnancy, for e.g., cataract due to congenital rubella. Most of these conditions can be identified during the newborn period, some would be classified as 'at risk newborns' and would require repeated examination and follow up.

2. RASHTRIYA BAL SWASTHYA KARYAKRAM (RBSK)

Defects at Birth, Deficiencies, Diseases specific to childhood and Developmental delays including disabilities, “4Ds”, can either lead to untimely death of a child or a survival **with poor developmental outcomes**. Such long lasting adverse health outcomes can be addressed only through early screening and timely management.

Extending preventive and promotive health as an approach for selected health conditions along with provision of free curative management, will help the marginalized and underprivileged population by reducing their out of pocket expenditure thereby influencing public health expenditure. This, in the long run, will improve the quality of our national human resource pool.

Keeping this in view, Ministry of Health and Family Welfare, introduced “Child Health Screening and Early Intervention Services” as **Rashtriya Bal Swasthya Karyakram-RBSK** under National Health Mission. These services under RBSK are to cover all the thirty selected health conditions through their screening, early detection & free management, for children from birth to 18 years of age.

Selected Health Conditions for Child Health Screening & Early Intervention Services under RBSK

<p>Defects at Birth</p> <ol style="list-style-type: none"> 1. Neural tube defect 2. Down's Syndrome 3. Cleft Lip & Palate / Cleft palate alone 4. Talipes (club foot) 5. Developmental dysplasia of the hip 6. Congenital Cataract 7. Congenital deafness 8. Congenital heart diseases 9. Retinopathy Of Prematurity 10. Strabismus and eye movement disorder (specially nystagmus) 	<p>Deficiencies</p> <ol style="list-style-type: none"> 11. Anemia especially Severe anemia 12. Vitamin A deficiency (Bitot's spot) 13. Vitamin D Deficiency (Rickets) 14. Severe Acute Malnutrition 15. Goiter
<p>Child hood Diseases</p> <ol style="list-style-type: none"> 16. Skin conditions (Scabies, fungal infection and Eczema) 17. Otitis Media 18. Rheumatic heart disease 19. Reactive airway disease 20. Dental caries 21. Convulsive disorders 	<p>Developmental delays and Disabilities</p> <ol style="list-style-type: none"> 22. Vision Impairment 23. Hearing Impairment 24. Neuro-motor Impairment 25. Motor delay 26. Cognitive delay 27. Language delay 28. Behavior disorder (Autism) 29. Learning disorder 30. Attention deficit hyperactivity disorder
<p>31. Others: Congenital Hypothyroidism, Sickle cell anemia, Beta thalassemia (Optional)</p>	

3. TARGET GROUP UNDER UNIVERSAL EYE SCREENING

The primary target age group is the early neonatal period which is the most critical time for identification of any eye related disorder and its management. The broad groups are as under:

Categories	Age group	Tools
SNCU graduates for Universal Eye Screening	Birth till discharge	Pictorial tools
Babies born at all delivery points (other than SNCU admissions) for Universal Eye Screening	Birth till discharge (within 48-72 hours of delivery)	Pictorial tools
Preterm Newborns for ROP including SNCU admissions for Universal Eye Screening plus ROP	First screening at 4 weeks of birth; those born before 30 weeks to be done at 2-3 weeks	Pictorial tools plus ROP Screening Instruments

This Screening would be carried out by medical officers, ANM of the delivery points, pediatrician and staff nurse of the SNCU with the help of DEIC optometrist. Management would be done by the ophthalmologist.

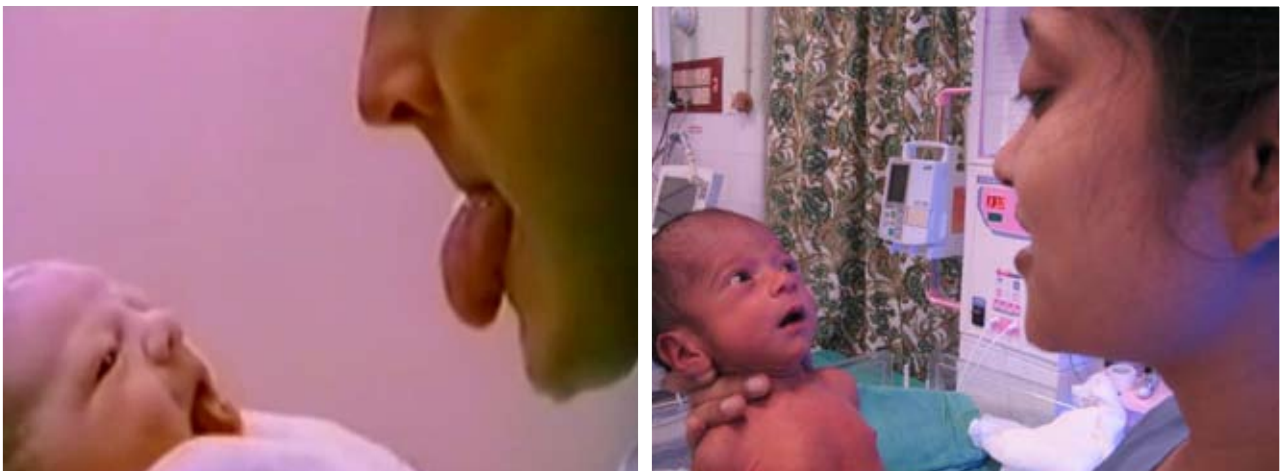
Timing is one of the important factors that make the treatment successful in eye related disorders, because some disease can advance very quickly and delayed treatment often reduces the chances of success. If we are able to identify the eye disorders right at birth and/or during the stay of High Risk Babies at SNCUs/ NICUs we are utilizing the window of opportunity to treat the disorder at the earliest and thus preventing developmental delays in these children.

GUIDELINES FOR: UNIVERSAL EYE SCREENING OF NEWBORNS

UNIVERSAL EYE EXAMINATION IN NEWBORNS

Vision is one of our five senses. Being able to see gives tremendous access to the developing brain of the newborn, helping them to learn about the world around—people’s faces and the subtleties of expression; what different things look like and how big they are, and the physical environments where the growing infant lives and moves, including approaching hazards. When a child has a visual impairment, it is a cause for immediate attention. That’s because **so much learning typically occurs visually**.

The fact that 40 per cent of the human brain is devoted to processing visual information shows the complexity and importance of this remarkable sense.



WHAT IS VISION? HOW DOES THE EYE WORK?

Vision is the **perceptual system** that is most suited for gaining information about the environment, particularly information about shape and space. Vision also is an important factor in early interactions between the infant and the parent(s). It is not surprising that children who have reduced sensory information because of vision impairment often find it more difficult to acquire various developmental skills and therefore demonstrate delays in development. *Cognitive development is delayed in children who have severely impaired visual function*, compared with children who have better vision. Early cognitive development and motor development are interrelated and can affect a child’s ability to interact with objects and people. In particular, object concept (understanding the relatedness of objects to other objects, events, persons, and experiences) and object permanence (understanding that something still exists even when it is not present) tend to be delayed in young children who are blind. Blind children’s delays in obtaining the object concept

can then result in delays in understanding other concepts. Good vision is essential for proper physical development and educational progress in growing children. The visual system in the young child is not fully mature. Two things are critical:

- a. *Equal input from both eyes is required for proper development* of the visual centers in the brain.
- b. If a growing child's eye does not provide *clear focused image to the developing brain*, then permanent irreversible loss of vision may result.

*Eyes and Brain normally work together to make 'vision'
The brain makes sight from signals given to it by the eyes.*

Eye and Vision: Vision occurs when the *eye receives images and transmits them to the brain*. Vision is a complex process that involves the eye, the brain, and the pathways between them. The eye has a system similar to a video camera connected to a computer that controls the amount of light allowed in and then focuses light rays onto the back of the eye to be transmitted to the brain. This system includes the *eyelids*, the *cornea* (a clear layer that covers the front of the eye), *the iris* (the circle of color around the pupil), the *pupil* (the black center of the eye that controls the amount of light), and a *lens* (the part of the eye that focuses the image)

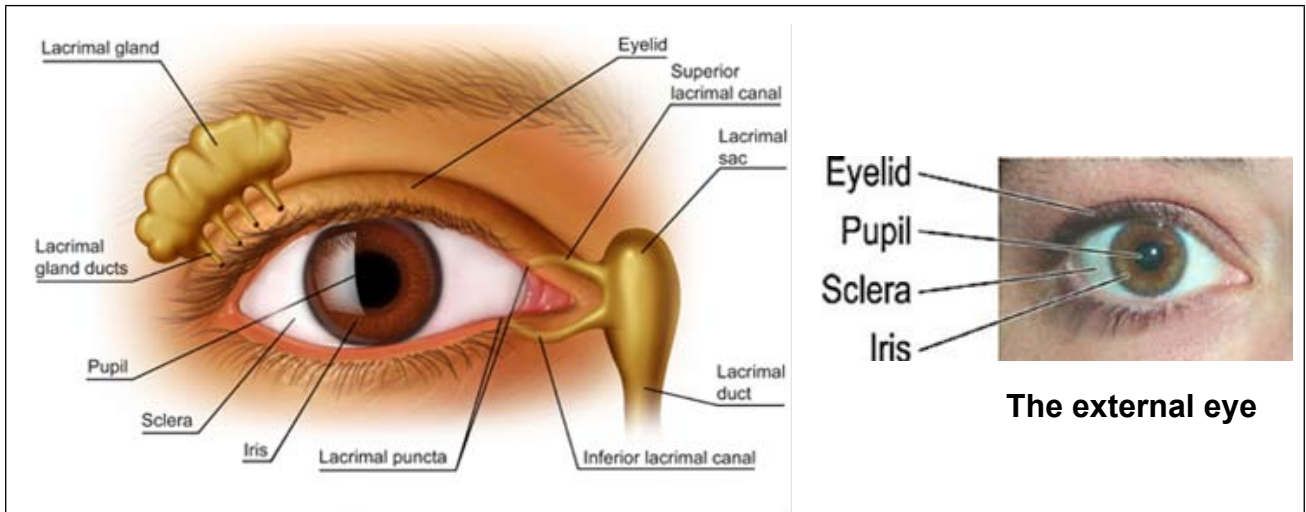
Visual impairment can be the result of a problem either in the eye itself or in the visual nervous system. A child's diminished ability to see may be related to a problem with any one or more of the following:

- allowing the light to pass through the eye
- focusing the light appropriately on the retina
- causing a reaction to occur within the photoreceptors of the retina
- transmitting the information via the optic nerve and visual pathways
- receiving/interpreting visual information by the brain
- integrating the information and providing appropriate feedback to the eye and extraocular muscles so that fixation can be maintained on the target

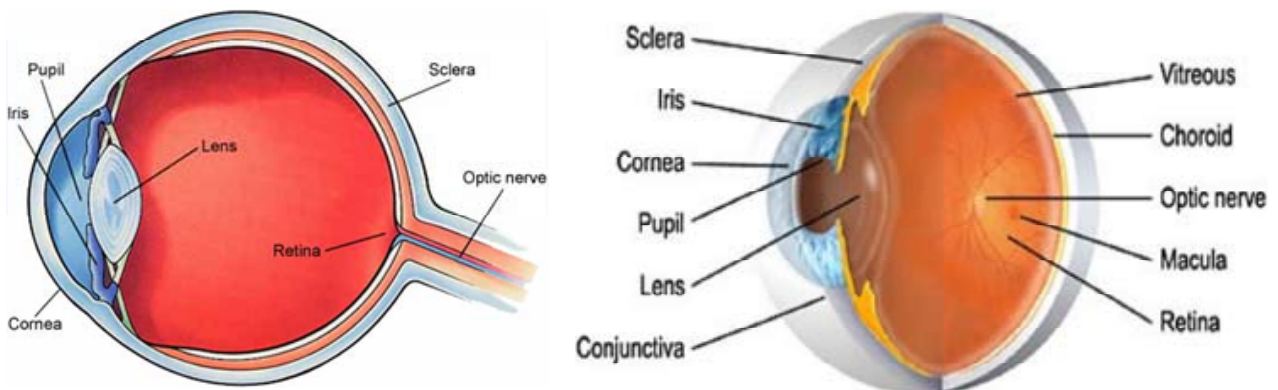
Newborns considered high risk for vision impairment even if initial examination of eye is normal include:

- Premature infants
- Those with a family history of congenital glaucoma or congenital cataracts or retinoblastoma in childhood, retinal dystrophy/degeneration or systemic diseases associated with eye problems
- Those with a family history of strabismus, amblyopia and/or sensori-neural hearing loss
- When any opacity of the ocular media is seen during newborn examination
- Infants with neuro-developmental delay

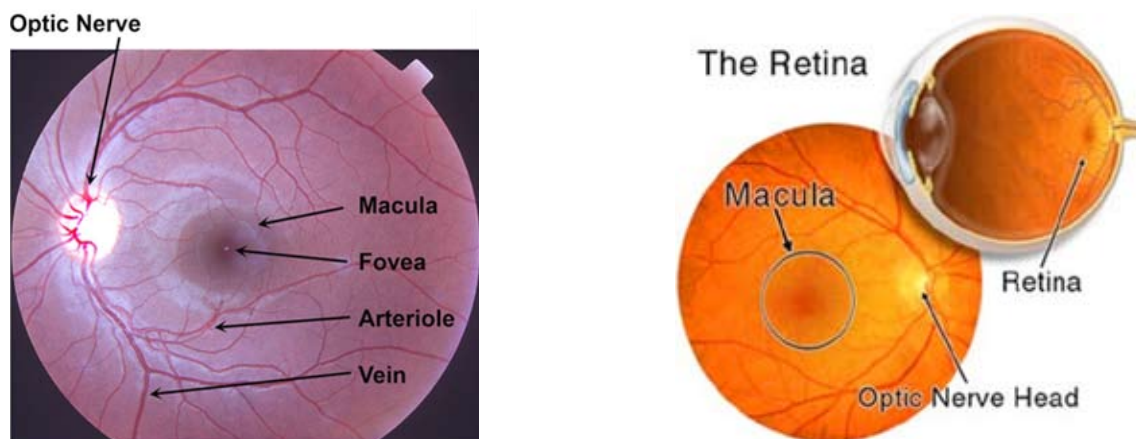
BRIEF OVERVIEW OF EYE ANATOMY, PHYSIOLOGY AND TERMINOLOGY



Cross section of the eye

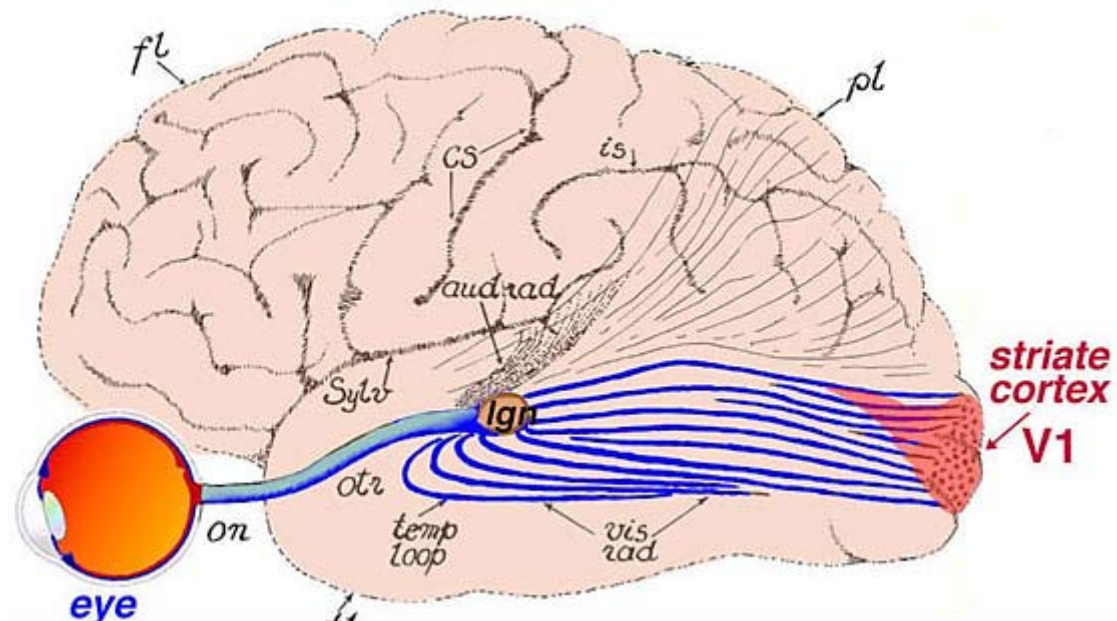


Retinal image through ophthalmoscope



Another important part of the eye is the retina. The retina is at the back of the eye, and it contains different types of light-sensing nerve cells generally classified as photoreceptors.

The retina and optic nerve, as seen through the pupil. Nervous impulses pass from the retina to the brain via the optic nerve



The striate cortex is where nervous impulses from the eye are converted into an image of the visual world

I. Sclera

The tough coat of the eyeball is called the sclera. It is white.

II. Conjunctiva

The conjunctiva is a thin, transparent mucous membrane which lines the under surface of the upper and lower eyelids and the front of the eye, except the cornea. Small blood vessels can be seen in the conjunctiva. If infection is present the conjunctiva becomes red and inflamed.

III. Cornea

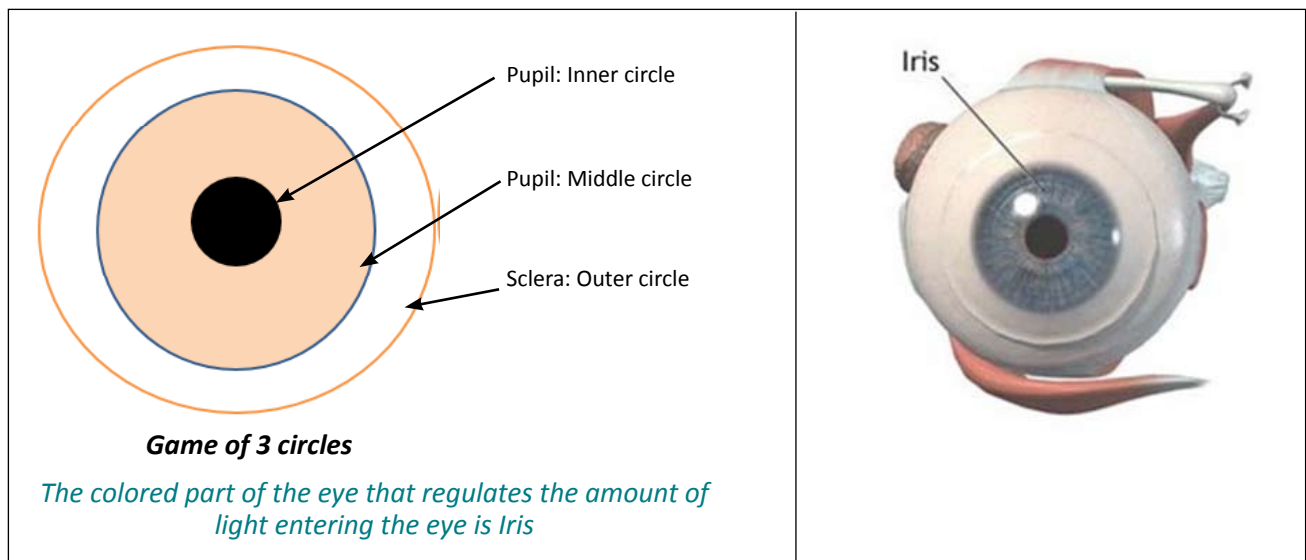
The front surface of the eye, the cornea, is a transparent, smoothly curved surface which focuses light entering the eye, providing most of the eye's focusing power of the eye. The surface is kept smooth and in good condition by tears which are spread over the surface by normal blinking. Loss of transparency due to scarring is a common cause of visual impairment in children. A scarred or white cornea can not only cause a cosmetic problem for the child but also affects the cognitive development.

At birth the cornea should be completely clear. Check for abnormal corneal size, normally 9-10.5 mm at birth.

IV. IRIS and PUPIL

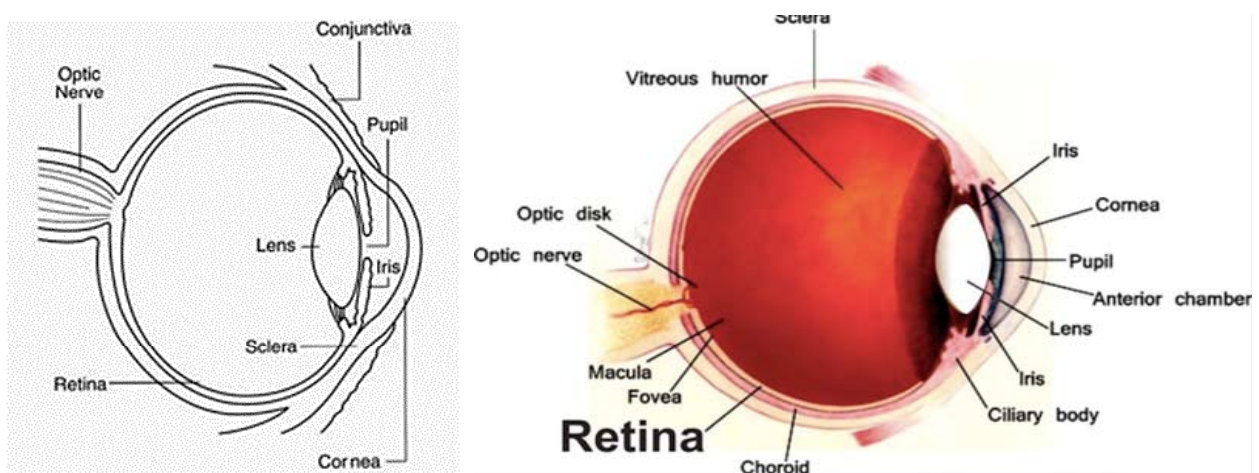
The colored part of the eye is the IRIS. In Indians it is brown. The Iris has a hole in the center called the PUPIL through which light enters the eye. In bright sunlight the pupil becomes very small; in darkness, the pupil becomes larger.

Controlling the amount of light entering the eye, the pupil can also assist in focusing light, to give a better “depth of field”.



Lens is the clear part of the eye behind the iris that helps to focus light on the retina

Retina is the light-sensitive tissue lining in the back of the eyeball that sends electrical impulses to the brain.



V. Lens

The lens of the eye lies just behind the iris and pupil. It should be completely transparent and in a healthy eye it is impossible to see the lens with a torch. The lens is also responsible for focusing the light that enters the eye. The lens changes shape for near vision, as a result of contraction of the muscles in the ciliary body. This process is known as accommodation.

Loss of transparency in the lens can be due to a wide variety of causes and is called cataract. Although it is much more common in older people, it is also a major cause of visual impairment in children worldwide.

Congenital cataract needs to be operated as early as possible as a delay can lead to permanent loss of vision.

VI. Fluids inside the eye

Between the cornea and the lens is the anterior chamber which is filled with a transparent watery fluid, called aqueous humour. This fluid is constantly produced by the ciliary body, and it escapes from the eye through channels at the front of the eye. If the fluid cannot escape then the pressure inside the eye increases, leading to a condition called glaucoma, which can lead to blindness.

Signs which suggest glaucoma in young children are an abnormally large eye, with a cloudy or opaque cornea. The eye may or may not be red.

The space between the back of the lens and the back of the eye is filled with a clear gel called the vitreous humour.

VII. Retina and optic nerve

The function of retina is to convert light energy into nerve impulses which are sent to the brain via the optic nerve where the perception of vision takes place. It is the photoreceptors in the retina that convert the light into “nerve impulses” that travel through the optic nerve to the brain. The brain then interprets these nerve impulses and produces an image. Not only is an image produced, but also information is received about **important characteristics of the image**, such as its **placement, motion**, and **localization** in space.

*However Cornea, pupil, lens and all the structures outlined earlier need to produce a **clear and focused image** on the retina, which is **the “light sensitive” part of the eye**, and is analogous to the film in a camera. The major landmarks are the **Optic disc** which is the exit of the optic nerve, and the **Macula** which is the area about 4mm across and which includes the **Fovea** (the most important point in the retina for detailed central vision) at its center. The retina is divided into two layers, the **inner “nerve” or neural layer or photoreceptors of retina and the outer pigment layer**. The neural retina contains the cells **called Rods and Cones** or photoreceptors which convert *light into electrical signals* which are eventually interpreted by the brain as a visual image. This process depends on the presence in the rods and cones of substances called photo pigments which change the shape of their molecules when they absorb light energy.*

- a. Rod cells are the receptors for night vision and ‘see’ everything as shades of gray.
- b. Cones are the receptors for daylight vision and respond to colors, movement, and high- and low-contrast.
- c. The density of the rods and cones varies in different parts of the retina. The rods are absent at the fovea, the cones on the other hand are most dense at the fovea.
- d. Both rods and cones contain photo pigments (light-sensitive molecules), but whereas all rods contain the same photo pigment, the cones contain three different types of photo pigment. One group of cones responds especially to blue light, one group to red and one to green light.

VIII. Visual cortex (or striate cortex)

The brain interprets the nerve impulses transmitted from the retina via the optic nerve and produces an image. The striate cortex or Primary visual cortex is where nervous impulses from the retina are converted into an image of the visual world. But that is not enough. One wants important **characteristics of the image such as its placement, depth and motion** including the **colour, form and texture** of the object.

EYE EXAMINATION

Examination of the eyes immediately after birth should be part of routine examination at birth.

Purpose of eye examination of newborn

Early Eye examination is vital for the detection of those conditions, which if not treated promptly can not only result in blindness, but also lead to problems with cognition or school performance or may signify serious systemic disease or at worst threaten the child's life.

The critical period of brain development happens in the first two years of life. Of the total 18 cm gain in head circumference of an individual during the lifetime, 12 cm increase happens in the first year of life and 3 cm in the second year of life. Eyes are a window to the brain and help in development during the critical period.

Through **early identification** of the **treatable conditions** of the ocular system, such as congenital cataract, congenital glaucoma and retinoblastoma, followed by referral for prompt treatment can save a child's eye and improve the quality of life through improving the quality of vision.

Early identification of those conditions which are **not treatable**, such as structural abnormalities of the eyes, requires early rehabilitation in the critical period as this would help to promote motor and psychosocial development of the growing child enabling the child to live a fuller life.

Steps in eye examination

- Ocular history
- External examination of the eyes
- White reflex with a torch
- Red reflex examination with an ophthalmoscope

Ocular history

Ask the parents the following:

- Do either of the parents have an eye condition which was present since birth?
- Do any brothers or sisters of the child have an eye or vision problem?
- Did the mother have a rash during the pregnancy of this child?

External Examination of the Eye:

Needs to learn to focus on

- Examining the eye with a torch

TOOLS REQUIRED FOR NEWBORN EYE EXAMINATION: AGE SPECIFIC SCREENING: NEWBORN

1. **Ocular history: Identifying Risk factors for vision impairment for future follow up** even if initial eye examination is normal at birth:

- a. **Family history of conditions** causing blindness or severe visual impairment (e.g., Congenital cataracts, Congenital glaucoma, Congenital squint, Congenital nystagmus, Familial Exudative Vitreoretinopathy, Retinoblastoma, and certain metabolic and genetic diseases)
- b. **Family history** of Strabismus, Amblyopia and/or sensori-neural hearing loss
- c. **Prenatal and birth history:**
 - **Birth asphyxia,**
 - **Intrauterine infection,**
 - **Prematurity,** especially low birth weight babies (less than 2000 gm)
- d. **Congenital conditions:**
 - **Albinism**
 - **Brain lesion noted on newborn brain imaging**
 - **Chromosomal abnormalities, such as Down syndrome**
- e. **Other structural birth defect especially involving the facial structures**
- f. **Others: Hydrocephalus *Infectious disease (e.g., toxoplasmosis, cytomegalovirus, herpes simplex) *Periventricular Leukomalacia (PVL)**
- g. **Any stage of ROP even if it regresses**

Discharge slip for the newborn must accompany with an advice for follow up for vision examination, even if initial eye examination is normal at birth

2. External examination of the eye:

- | | |
|---|---|
| <ol style="list-style-type: none"> a. External examination of the eye is a general inspection of the eye including the orbits, globes, eyelids, eyelashes, tear sacs, and conjunctiva. b. External examination for any abnormality with Sclera, Cornea, Iris, Pupil, Lens | <ol style="list-style-type: none"> a. Pictorial tool at all delivery points b. Screening cum referral card for eye problems |
|---|---|

3. Use Torch light or Flash light to examine:

- a. **External evaluation** for obvious ocular malformations and infections
- b. **Pupillary examination: Light reflex:** Pupillary reaction is evaluated by testing constriction of each pupil both when it is stimulated directly by light and when the other eye is stimulated by light (consensual light reflex).
- c. **Pupillary examination: for white reflex**

White pupillary reflex is the whitish appearance of pupil. This condition is also known as leukocoria. (From the Greek “leukos” meaning white and “kore” meaning pupil) and is the name given to the clinical finding of a white pupillary reflex. It can occur in number of conditions. Leukocoria can be caused by abnormalities in the lens (e.g., cataract), vitreous (e.g., hemorrhage), or retina (e.g., retinoblastoma). Following are the causes of white pupillary reflex in early life.

1. Congenital Cataract

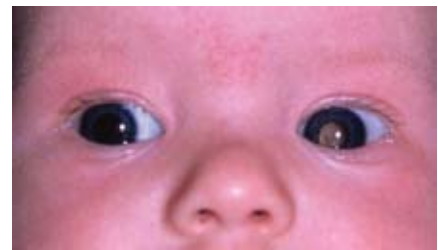2. Congenital glaucoma

3. Anterior Persistent Hyperplastic Primary Vitreous (APHPV): Developing lens has nutritional vascular supply which regresses after birth. In APHPV primary vitreous of fetal life persists along with the vascular after birth. It is present behind the lens and don't allow light rays to reach retina and give white pupillary reflex on examination.

4. Familial Exudative Vitreoretinopathy, Autosomal Dominant: Familial exudative vitreoretinopathy (FEVR) is a genetic eye disorder affecting the growth and development of blood vessels in the retina of the eye. This disease can lead to visual impairment and sometimes complete blindness in one or both eyes. FEVR is characterized by exudative leakage and hemorrhage of the blood vessels in the retina, along with incomplete vascularization of the peripheral retina, and can easily be confused with retinopathy of prematurity in premature infants.

5. Retinoblastoma: It is a congenital tumor of retina. It is a life threatening malignant condition and it usually occurs within first three years of life.

6. Corneal Opacity



4. See Red Reflex through Direct Ophthalmoscope:

- a. **Red reflex test:** The red reflex is the red light reflection seen when examining the eye with an ophthalmoscope. This test is used to determine whether there is an opacity (cloudiness) of the cornea, a cataract, or a retinal detachment or disorder.
- b. **Binocular red reflex:** The Bruckner test is a comparison of the red reflexes when viewed from both eyes at the same time. This test is used to assess symmetry of alignment and refractive errors of the eyes.

Unequal red reflex or absence of red reflex: 1. Congenital Cataract 2. Anterior Persistent Hyperplastic Primary Vitreous (APHPV) 3. Familial Exudative Vitreoretinopathy (FEVR) 4. Retinoblastoma 5. Severe Anisometropia and Strabismus



Universal eye screening for all newborns: Key points to be followed

Inspection and examination using torch and Direct Ophthalmoscope	
Eye lid & facial examination	Any gap in the eyelid, any swelling, drooping eyelids,
Any Facial marks	Any pigmented marks around the eye
Look at the eyes	One or both eyes is too small
	One or both eyes is not developed
	One or both eyes is too big
Conjunctiva	Redness with discharge
Sclera (Outer circle): look for Any abnormality	Abnormal growth (Dermoid) or Blue sclera
Cornea (Middle Circle): Look for Corneal size and Transparency	Large cornea (Megalocornea, Congenital glaucoma)
	Small cornea (Micro cornea)
	Hazy cornea (corneal opacity, congenital glaucoma)
	Gap in the iris (Coloboma)
Pupil (Inner circle):	Pupil circle abnormal shape (Coloboma)
	White reflex (with a torch): congenital cataract, any abnormal lesion arising from vitreous and retina.
	Red reflex with Direct Ophthalmoscope Abnormal: Congenital cataract, any abnormal lesion arising from vitreous and retina.

OCULAR ABNORMALITIES WHICH MAY BE PRESENT AT BIRTH

Abnormalities of the eye which can readily be detected by examination of the eye:


- **Eyelid abnormalities:** the eyelids may be too narrow, or the eyelid(s) may be droopy. (Can be familial)
- **Abnormally small eye** (microphthalmos) or **absent eye** (anophthalmos) from birth. These conditions can affect one or both eyes. (Can be familial)
- **Coloboma**, where a portion of the structure of the eye is missing. Can be familial; commonly involves eyelid, iris, choroid, retina. In coloboma iris, pupil will be irregular with a defect in inferior nasal quadrant.
- **Congenital glaucoma**, where the pressure inside the eye(s) is too high. In the newborn this can lead to an eye that is larger than usual. The cornea may also be cloudy or opaque.
- **Corneal opacity.** Very occasionally infants can be born with cloudy or opaque corneas. This is not caused by Vitamin A deficiency which affects older children. (Can be familial)
- **Congenital cataract**

Abnormalities of structures inside the eye which may only be detected by assessing the red reflex at birth

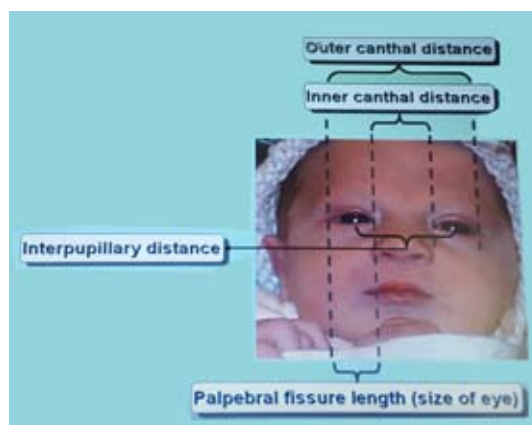
- Congenital cataract, where the lens of the eye is cloudy. This can affect one or both eyes, and occurs in around one in 3000 births. Can be familial.
- Retinoblastoma, a rare but life-threatening malignant condition of the retina. This can be present at birth or become apparent during the first few weeks of life. It can be familial.

I. Inspect the eyes:








- Note the **position/spacing and size of the eyes**, width of palpebral fissures.
- **Asymmetry of the eyes** may be the result of prominent epicanthal folds, a difference in the size of the globes, or ptosis.
- Any redness, discharge or lid matting to rule out conjunctivitis and nasolacrimal duct obstruction.
- Abnormal slant, widened or narrow palpebral fissures can be part of a **syndrome complex due to chromosomal or genetic disorder**.



1. Black: Inner canthal distance
2. Green: Palpebral fissure length
3. Blue: Interpupillary distance
4. Red: Epicanthic fold

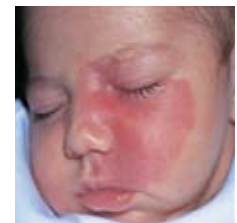

For normal eye, the inner canthal distance is equal to palpebral fissure length

A. Eye spacing		B. Slant of eye (Palpebral fissure)		
Wide set: Hyper-telorism: Increased inter-pupillary distance	hypotelorism 			
Close set: Hypo-telorism: decreased inter-pupillary distance	normal  hypertelorism 	Normal slant	Upward slant	Downward slant
C. Epicanthic folds				
A fold of skin which arcs from below the eye into the upper lid				

II. Inspect eyelids and face:

- Swelling of the eye lids is Common after birth
- Check for any gap in the eyelids: Coloboma of eyelids
- Check for any hemangioma of the eyes (Port wine stain)



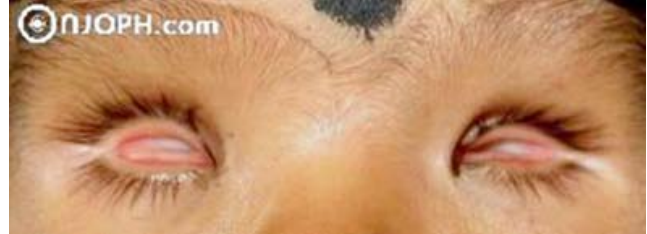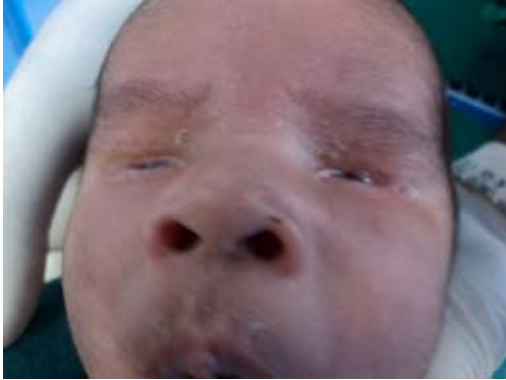Port wine stain

A port wine stain is a vascular birthmark caused by abnormal development of blood vessels in the skin. A port wine stain is sometimes referred to as a capillary malformation. A port wine stain is a flat, red or purple mark on the skin that is present at birth. Over time, the port wine stain may become thicker, darken and develop a 'cobblestone' appearance with raised bumps and ridges.

- Glaucoma:** Children with a port wine stain around the eye have an increased risk of glaucoma. About one in four of these children develop glaucoma. Glaucoma is raised pressure within the eye, which can lead to blindness if it is not treated. Treatment is usually by eye drops and occasionally an operation.
- Sturge-Weber syndrome:** If a newborn's port wine stain is on the skin around the eye, forehead or scalp, there is a chance that he or she may have a condition called Sturge-Weber syndrome. Besides the port wine stain affecting the skin, it may also involve blood vessels over the surface of the brain, which can cause seizures (fits or convulsions). If there is any suspicion that your child is at risk of Sturge-Weber syndrome, they will need to be checked over by a neurologist.
- Klippel Trenaunay syndrome:** A large port wine stain on the arm or leg might be associated with extra growth of that limb and is referred to as Klippel Trenaunay syndrome. This may need a multidisciplinary review by dermatologists, laser specialists, and general, orthopedic and vascular surgeons.
- Proteus syndrome:** Port wine stains can be associated with Proteus syndrome, which causes extra growth in some parts of the body, mainly the hands and knees, but also others. This extra growth can affect movement, particularly if a joint is involved. Children with Proteus syndrome need regular checkups with a multidisciplinary team including dermatologists, general, orthopedic and vascular surgeons and laser specialists.

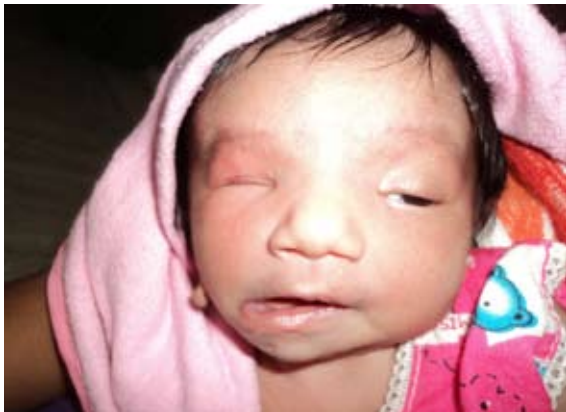III. Look at the eye

Abnormally small eye (microphthalmos) or absent eye (anophthalmos) or Buphthalmos (large eye)

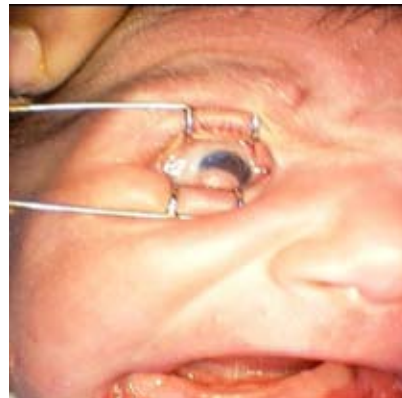

Bilateral anophthalmos

Anophthalmos – the eye socket is empty with no evidence of an eye. Both eyes affected or only one eye.

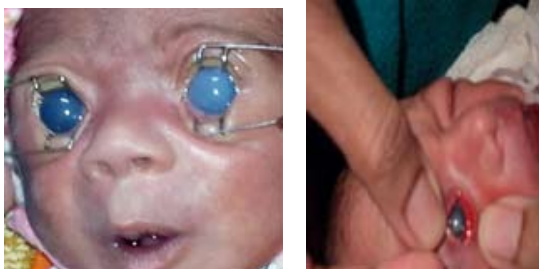

Microphthalmos



Same newborn with Microphthalmos, asymmetry of face and dermoid on the sclera

Microphthalmos: or Small Eye syndrome is a disorder in which one or both the eyes of the newborn baby are underdeveloped. Various genetic factors, which affect the early development of the eyes, are found to be responsible for this condition. Certain environmental factors may also contribute to the condition. Children with microphthalmos present with visual disturbances and learning disabilities.



Buphthalmos is a descriptive term which simply means an enlarged eyeball or ocular globe (usually without deformation or and intrinsic mass lesion).

Primary congenital glaucoma typically presents in the neonatal period with the classic triad of tearing, photophobia and Blepharospasm (involuntary twitching, blinking or closure of the eyelids) + conjunctival redness, corneal enlargement and corneal clouding.

IV. Look at the conjunctiva

Red eye with discharge: Conjunctivitis is an inflammatory disease characterized by conjunctival erythema, swelling, and discharge. Ophthalmia Neonatorum (ON), also called neonatal conjunctivitis, is an acute, mucopurulent infection occurring in the first 4 weeks of life, affecting 1.6% to 12% of all newborns, caused by chemical, bacterial, or viral processes.

Aseptic neonatal conjunctivitis: Chemical conjunctivitis accounts for most cases presenting as a mild, purulent conjunctivitis **within the first 24 hours of life**. It is most commonly associated with silver nitrate prophylaxis, or secondary to prophylaxis with other agents such as erythromycin or tetracycline. Chemical conjunctivitis is a self-limiting condition that does not require any diagnostic tests or treatment.

Bacterial and viral infections are major causes of septic neonatal conjunctivitis. Infants may acquire these infective agents as they pass through the birth canal during the birth process. e.g. gonococcal conjunctivitis.

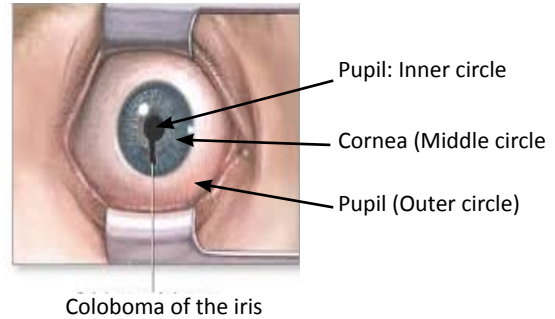
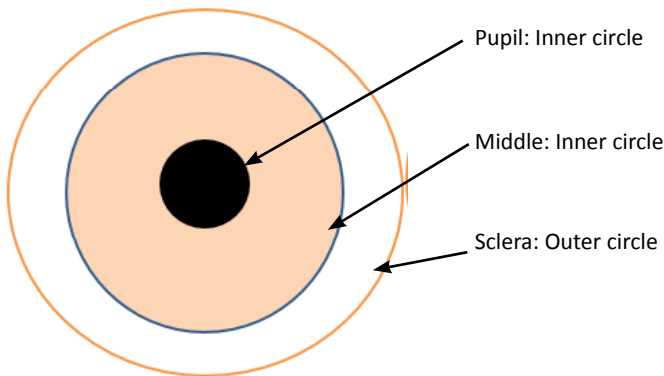
Chlamydia trachomatis: The incubation period is **typically 1 week after delivery**; however, it varies from **5 to 14 days or earlier** if membranes ruptured prematurely. The clinical manifestations vary from mild conjunctival injection with scant watery discharge to severe mucopurulent discharge with eyelid edema, chemosis, and pseudomembrane formation. **A 14-day course of systemic erythromycin (50 mg/kg/d, divided in 4 doses). Topical therapy is not indicated.**

Neisseria gonorrhoeae: The disease typically presents with profound chemosis, edema of the eyelids, and abundant purulent discharge that might be blood-tinged from superficial hemorrhage **within 2 to 5 days of birth**; however, it can manifest up to 2 to 3 weeks after delivery. Infants with gonorrheal ON should be hospitalized, **treated with frequent irrigation of the conjunctiva and intravenous or intramuscular administration of ceftriaxone (25 to 50 mg/kg, to a maximum dose of 125 mg), and evaluated for disseminated gonococcal disease (eg, arthritis, sepsis, meningitis)**. Various other bacteria commonly isolated from neonates with conjunctivitis include **Staphylococcus, Streptococcus and Haemophilus species**.

Care of the eyes: Neonates presenting with signs of conjunctivitis should have a conjunctival swab sent for Gram stain and culture. If Gram-negative diplococci are present on the Gram stain results, the infants and their parents should be treated immediately for presumed gonorrhea. Infants with chlamydial infection should be treated with oral antibiotics. **Most of all other forms of bacterial conjunctivitis can be treated with topical antibiotics, with the exception of Pseudomonas infection.** Infants should be followed during their treatment and upon completion of therapy to ensure resolution of symptoms.

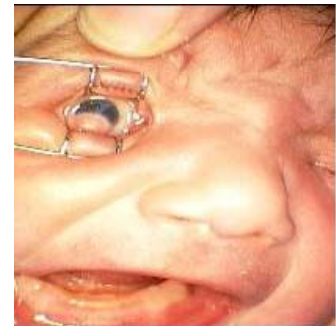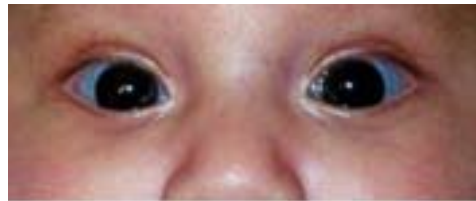Prevention: The eyes should be cleaned at birth and once every day using sterile cotton swabs soaked in sterile water or normal saline. **Ocular prophylaxis with 1% silver nitrate, 0.5% erythromycin ointment, or 1% tetracycline hydrochloride be given to all newborns, including those born by cesarean section, in the first hour after birth (recommended but not practiced).** It is important to note that routine ocular prophylaxis does not prevent chlamydial Ophthalmia Neonatorum. The practice of applying kajal in the eyes is not recommended because it may cause trauma, transmit infections like trachoma or may even cause lead poisoning. If the eyes are sticky they can either be managed by frequent cleaning using sterile cotton swabs soaked in normal saline or by instillation of 10% sulphacetamide eye drops every two to four hours. **Some neonates may develop persistent epiphora due to blockage of nasolacrimal duct by epithelial debris.** The mother should be **advised to massage the nasolacrimal duct area (by massaging the outer side of the nose adjacent to the medial canthus) 5 to 8 times a day, each time before she feeds the baby.**

V. Sclera, Cornea, Pupil, Iris, Fundus



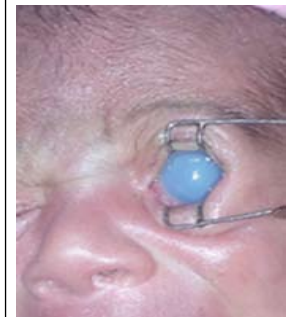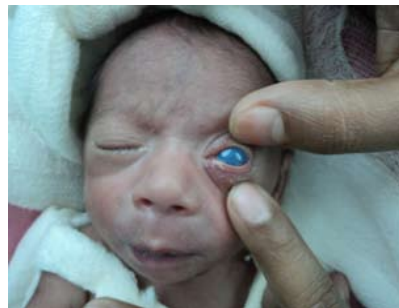Outer Circle

Look for Blue sclera, growth (Dermoid in goldenhar syndrome)



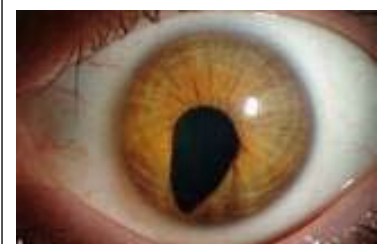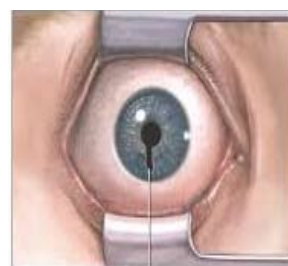
Middle Circle








- a) Large corneas that may appear cloudy.
- b) The pupil — the black center of the eye that normally changes diameter in response to light — is dilated.
- c) The iris (the colored portion of the eye) may show signs of atrophy.
- d) There may also be excessive watering and light sensitivity. **Congenital glaucoma**



Large cornea in **congenital glaucoma** compared with normal eye and normal cornea.

Round shape of Pupil and Iris is distorted:
Coloboma



 <p>Megalocornea a horizontal diameter of >12 mm</p>	 <p>Megalocornea a horizontal diameter of >12 mm</p>	 <p>Meaglocornea + Corneal opacity</p>
<p>Inner Circle</p>		
<p>On torch examination - white eye indicates Congenital Cataract</p>		
<p style="text-align: center;"><i>Congenital Cataract</i></p>		
<p>VI. Red reflex</p>		
<p>Red reflex either by Ophthalmoscope or Camera: Red reflex is actually seeing the curtain of eye (Retina) which is red. A red glow means the media through which the light has traveled is clear i.e. cornea, lens etc. are not opaque.</p>	 <p>Normal red reflex with ordinary Camera</p>	 <p>A white glow in a child's eye could be a sign of eye cancer. See RED or see an eye doctor.</p>

Red reflex

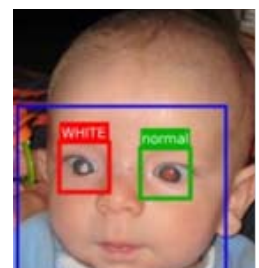
Done for early detection of potentially sight and life-threatening eye disease. Due to the early and time-limited plasticity and development of the eye, any blockage of light to the retina interferes with development of optic neural pathways and can have profound effects on later vision.

Valuable in screening the following conditions:




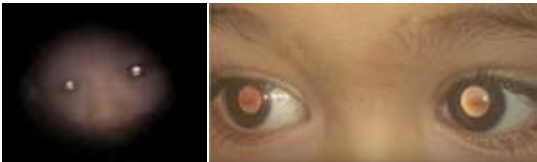

- Cataracts
- Retinoblastoma
- Vitreous abnormalities
- PHPV, FEVR

Principles of Red Reflex testing

- Assessment is to be done in a dimly lit or dark room.
- It can take 10 seconds from the time the lights go down to the time the pupil reaches maximal dilation.
- Stand 1.5 feet away from the child and look through the direct ophthalmoscope so that the entire face is in clear focus.

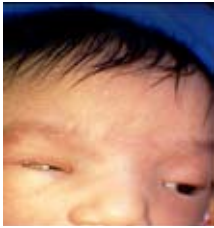

- Use a large enough aperture size so that both eyes including the face are illuminated.
- Use different angles to get the red reflex.
- Since the cornea, pupil, anterior chamber, lens, vitreous all are transparent the retina is visible to the examiner. If there is obstruction to the light due to any pathology, it affects the red reflex.

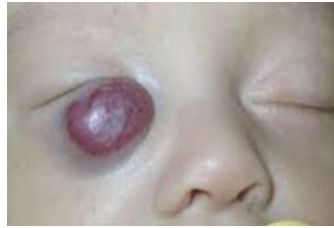	<p>Learn the parts of an Ophthalmoscope especially the disc aperture and the wheel to select the strength of a lens.</p>
	<p>Get the largest white circle of light by turning the disc of the aperture in the ophthalmoscope as shown:</p> <p>- Selection of Aperture Type</p> <p>There are five aperture choices which are changed by turning the Aperture Wheel.</p>
	<ul style="list-style-type: none"> ● From a distance of approximately 18 inches, visualize the fundi are individually and simultaneously (Bruckner test). Focus on the child's face. ● Viewing the retina obliquely, in addition to straight-on, may improve the detection of retinal mass lesion not involving the posterior pole.
<p>Try without dilating the eyes, If not possible then dilate the eyes.</p> <p>A red reflex examination preceded by pupil dilation with 1% tropicamide or a 1% tropicamide/2.5% phenylephrine mixture administered to each eye approximately 15 minutes before this examination.</p>	
<ul style="list-style-type: none"> ● Normal red reflex may be Orange in about 80% and Red in 20% in this part of world. ● In more darkly pigmented children, the reflex may be more gray than red. 	<p>Children who have an abnormal red reflex (e.g., dark spots, markedly diminished reflex, white reflex, and asymmetry) should be referred to an ophthalmologist.</p>
<p>Normal red Reflex:</p> <ol style="list-style-type: none"> 1. Bright 2. Contains no Silhouette 3. Symmetrical in character 	<p>Abnormal red reflex:</p> <ol style="list-style-type: none"> 1. Dark spots or other silhouettes 2. Markedly diminished reflex 3. White 

Recall the Steps: Pictorially

1. Check for EYELID abnormality



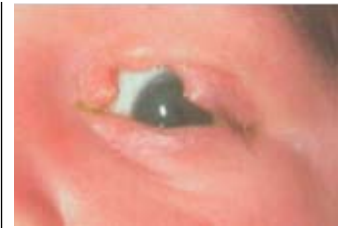
Eye lids may be too narrow



Hemangioma of eyelid

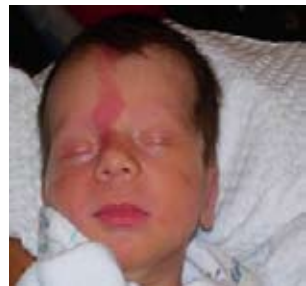

Droopy eye lid



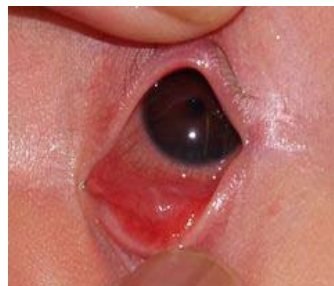Coloboma of eye lid

2. Check for Facial marks: (port wine stain or capillary hemangioma)

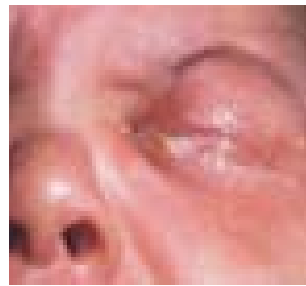


If present, the eyes need careful examination if possible by the local ophthalmologist

3. Look for red conjunctiva with eye discharge ophthalmic neonatorum

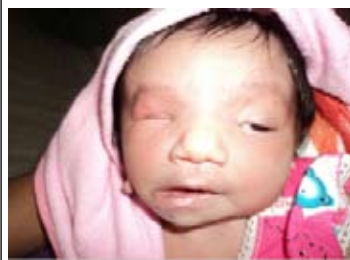

Red conjunctiva

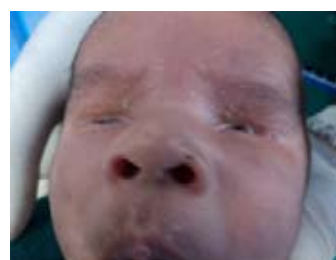

Eye discharge can be prevented by ocular prophylaxis i.e. cleaning the eyelids and birth, with instillation of antiseptic or antibiotic eye drops or ointment

4. Abnormally small eye (microphthalmos) or Absent eye (anophthalmos)

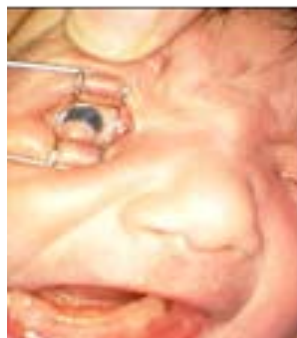

Microphthalmos

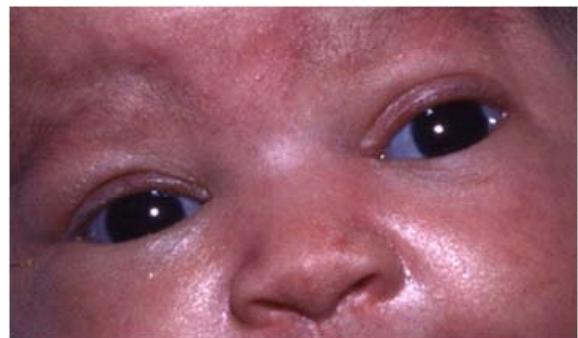

Anophthalmos – the eye socket is empty with no evidence of eye




5. Look for Blue sclera and any, growth on the sclera



Dermoid



Blue sclera

<p>6. Coloboma: A portion of the structure of eye is missing or a gap</p> <p>6 a): Eye lid incomplete</p> <p>6 b): Pupil round or not (coloboma of iris)</p>	 <p>coloboma of the eye lids</p> <p><i>Coloboma of the eye lid</i></p>	 <p><i>Coloboma of the IRIS</i></p>
<p>7. Corneal opacity:</p> <p>a) Look for Corneal clouding</p> <p>b) see for the size of the cornea</p> <ul style="list-style-type: none"> * Corneal clouding with large eyes * Corneal clouding with normal size eyes or cornea * Congenital cataract * Check for photophobia * Check for tearing 	 <p><i>Megalocornea</i></p>	 <p><i>Abnormally large eyes, with corneal opacity: Congenital glaucoma in newborn</i></p>
 <p><i>Corneal clouding in newborn</i></p>	 <p><i>Congenital cataract</i></p>	 <p><i>Corneal opacity without large eyes</i></p>
<p>8. Pupil area: see for any white reflex by using a torch: congenital cataract or vitreous / retinal pathology</p>	 <p><i>White eye</i></p>	
<p>9. See for absence of red/orange glow or any asymmetry in the red glow between the two eyes by using ophthalmoscope</p>		

SCREENING CUM REFERRAL CARD

Name: Baby of		Birth weight: - / - / - gm.		Gestational age at time of birth: WW/ DD: weeks and days			Estimated day of delivery: mm/dd/yyyy	
		Date of Birth: mm/dd/yyyy						
Any Risk factor*	PREMATURE BIRTH: at least 21 days before the Expected date of delivery	Delayed cry/Birth asphyxia	Has: Down syndrome, Birth asphyxia, hearing impairment or hydrocephalus	Birth defects involving the head or face	Birth weight: if less than 2000 gm.	Admitted in SNCU for > 4 days	Prolonged use of Oxygen >72 hours	Neonatal sepsis
Tick if yes ✓								
Any Family History early onset vision loss:	Family H/O: By asking early onset Eye problems: Tick if Yes✓			✓	✓	Relation	Condition with early onset Eye problems in family: Tick if Yes✓	
Family member (blood relatives)	1. Retinoblastoma (Congenital Tumor of eye)						8. Nystagmus (roving eye)	
	2. Severe refractive error, or any visual perceptual problems since child hood						9. Strabismus or crossed eye in other family members	
	3. Congenital cataract in other family members						10. Albinism in family	
	4. Congenital Glaucoma in other family members						11. Coloboma or cleft in eyes of other family members	
	5. Sickle cell disease						12. Retinitis pigmentosa in family	
	6. Amblyopia (lazy eye)						13. Aniridia	
	7. Unexplained Vision loss/ or blindness since early childhood						14 Optic atrophy	
	✓ Risk factor: ○ Family History: ○			If yes: ask for follow up even if the initial screen is normal				
VIS ASSESSMENT of New-born eye								
Maternal factors: Suspected of having a congenital infection or diseases during pregnancy? e.g., CMV, Toxoplasmosis, Maternal Venereal Conditions, Rubella: Yes/No: Tick if yes								
Facial features: Normal / Abnormal looking: any syndrome identified , any neurological condition identified								
Lids: Normal/swelling/droopy: RL: <input type="checkbox"/> <input type="checkbox"/> <input type="checkbox"/> <input type="checkbox"/>				Conjunctiva: Red/Normal R L: <input type="checkbox"/> <input type="checkbox"/>				
Red discharging eyes: Yes/NO (Look for Swelling, excessive watering, or discharge from eyes:)								
Mongoloid/ ante mongoloid slant/ epicanthic folds: TICK (Look for Abnormal slant, abnormal folds beneath the eyes (Epicanthic folds), distance between two eyes (more or less than normal), size of the eye opening (smaller than normal))								
Sclera: White/ red inflamed/ any growth: R L <input type="checkbox"/> <input type="checkbox"/> <input type="checkbox"/> <input type="checkbox"/>				Cornea: Transparent/ opaque/unequal both side: R L <input type="checkbox"/> <input type="checkbox"/> <input type="checkbox"/> <input type="checkbox"/>				
Large cornea /small cornea R L <input type="checkbox"/> <input type="checkbox"/>				Iris: Normal/cleft/abnormal color: R L <input type="checkbox"/> <input type="checkbox"/> <input type="checkbox"/> <input type="checkbox"/>				
Pupil: Circular/clear/white/unequal both side				Any other abnormality of the eye				
Pass: If all structures are normal				Rescreen/ Refer: If any abnormality is noted.				
* If risk factor, the child should be called for rescreening at the DEIC at 3 months.								

PICTORIAL TOOL FOR IDENTIFICATION OF EYE DEFECTS

1. Check for EYELID abnormality			
			
<i>a. Hemangioma of eye lid</i>	<i>b. Eye lids may be too narrow</i>	<i>c. Partially closed eye lid, unable to keep it open Droopy eyelid</i>	<i>d. Gap in eye lid (coloboma)</i>
2. Check for Facial marks: (port wine stain or capillary hemangioma)	3. Abnormally small eye (Microphthalmos) or Absent eye (Anophthalmos)		4. Look for red conjunctiva with eye discharge ophthalmic neonatorum
			
			<i>Eye discharge+ red conjunctiva</i>
5. Coloboma: A portion of the structure of eye is missing or a gap	6. Look for Blue sclera and any, growth on the sclera (Dermoid in goldenhar syndrome)	7. Pupil area: congenital cataract or vitreous / retinal pathology see for any white reflex by using a torch	
			
<i>Coloboma of both eyes</i>	<i>Dermoid</i>		
8. Corneal opacity			
			
<i>Corneal clouding</i>	<i>Congenital cataract</i>	<i>Abnormally large eyes with corneal opacity: congenital glaucoma in new-born</i>	
			
9. See for absence of red/orange glow or any asymmetry in the red glow between the two eyes by using ophthalmoscope			<i>Red reflex</i>

FOLLOW UP

Mandatory follow up for all “At risk” newborns for vision testing if:

1. Born before **36 weeks** or birth weight **< 2000 gm.**
2. History of **family** member having **poor vision** or any eye problem in **childhood**
3. Family history of any **tumor** of eye
4. Had **any stage of ROP**
5. History of **not crying at birth** or delayed cry after 5 minutes
6. Stay in the **SNCU/NICU** for more than 4 day
7. **Any Abnormal looking child or if** any syndrome **identified**, or if any neurological condition **identified**
8. Any birth defect or **congenital abnormalities of other systems** or **any problem associated with eye**
9. Any **concern of the parents** regarding vision at any time or **the medical officer / pediatrician at the time of discharge**

* Please mention in the discharge along with the date and venue for the follow up.

* Follow up includes Eye examination including Refraction to be done in all children at 6 monthly interval for next 24 months.

Action required

Eyelid abnormalities	Refer to tertiary eye care services for assessment as surgery may be required
Abnormally small or absent eye(s)	Refer to tertiary eye care services for diagnosis followed by rehabilitation, if both eyes affected
Congenital glaucoma	Refer to tertiary eye care services for assessment and surgery
Coloboma	Refer to tertiary eye care services for diagnosis followed by rehabilitation, if both eyes affected
Corneal opacity	Refer to tertiary eye care services for diagnosis followed by rehabilitation, if both eyes affected
Abnormal red reflex:	
Congenital cataract	Refer to tertiary eye care services for assessment and surgery
Retinoblastoma	Refer to tertiary eye care services for surgery or other treatment

The following children are at a higher risk of eye problems:

- *family history of congenital cataracts, retinoblastoma, metabolic or genetic diseases*
- *other congenital abnormalities, such as congenital heart disease*
- *evidence of intrauterine infection*

GUIDELINES FOR OPERATIONALISING RETINOPATHY OF PREMATURITY (ROP)

CONTENTS

1. Introduction to ROP
2. Classification of ROP: Location/Extent/Severity
3. Risk factors for ROP
4. Screening for ROP
 - 4.1 Whom to screen
 - 4.2 When to screen
 - 4.3 Duration and frequency
 - 4.4 Preparation
 - 4.5 Place of examination
 - 4.6 Equipment Check list
 - 4.7 Screening Procedure
5. Management of ROP
6. Follow up examination in SNCU/NICU
7. Complications of ROP
8. Issues, Follow-up & Counselling
9. Other modalities of treatment
10. ROP recording form
11. Preventive measures
12. Quality Improvement
13. Strategies for Control of visual loss from ROP
14. Exercise on ROP

1. INTRODUCTION

Retinopathy Of Prematurity (ROP) is a retinal disorder of low birth weight premature infants. It can be mild with no visual defects, or it may become aggressive with new vessel formation (neo-vascularisation) and progress to retinal detachment and blindness. The stimulus for the abnormal growth of blood vessels comes from the peripheral immature retina. Nearly one third to half of neonates undergoing screening may show some degree of ROP which fortunately regresses on its own in majority of affected infants, in a few it progresses to the stage of retinal detachment and blindness. **Timely screening and treatment of ROP can prevent blindness and minimize visual handicaps.**

- *Incidence: Studies from India have reported ROP in 20% to 52% of screened neonates. More recent studies reporting lower rates of ROP ranging from 20% to 30%.*
- *The major risk factor is very low birth weight, prematurity and high oxygen concentration. Associated risk factors are acidosis, apnea, PDA, sepsis, intra-ventricular hemorrhage, and blood transfusion.*
- *May lead to complete blindness forever, if not screened and treated in time after which even with the best of treatment, no substantial improvement in outcome would occur.*

1.1 Objectives of the section

To help the health care providers in clinical decision-making by providing evidence-based information on ROP.

1.2 Clinical questions

The clinical questions for these guidelines are:

- a. Who should be screened for ROP?
- b. When to screen for ROP?
- c. What should be the frequency of Screening after the initial examination?
- d. How should these babies be screened for ROP?
- e. How should they be managed?
- f. How to follow up these babies?

1.3 Target population

These guidelines are for the management of infants with the risk of developing ROP and those with the established disease.

1.4 Target group

These guidelines are meant for concerned health care providers based at **District hospital, SNCU and DEIC.**

2. CLASSIFICATION OF ROP: LOCATION/EXTENT/SEVERITY

International Classification of ROP (ICROP) is used for classifying ROP. ROP is categorised based on the severity of the disease into stages (0-5), location of the disease into 3 zones (Zone 1-3), extent of the disease based on clock hours (1-12) and the presence of plus disease.

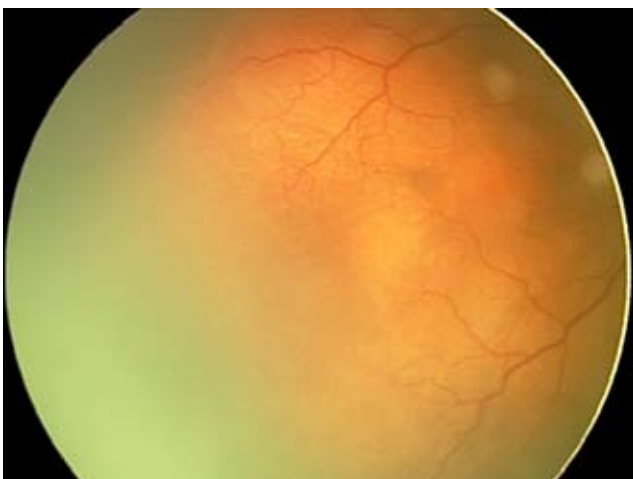
2.1 Disease location

The retina is divided into three concentric circles, each centered on the optic disc. The retinal vessels grow out from the optic disc to the periphery and the designation of zones corresponds to the vascular developmental pattern.

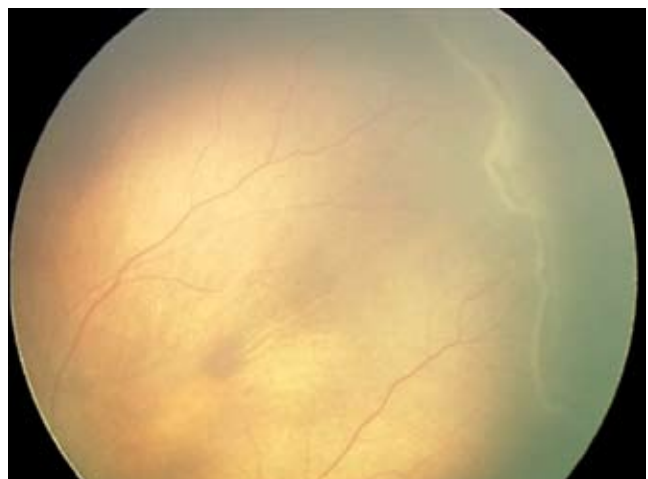Zone1: Defined by a circle whose radius is twice the distance from the centre of the optic disc to the centre of macula (Fovea).

Zone 2: Defined by a circle whose radius is the distance from the centre of the optic disc to the nasal margin of the retina (ora serrata)

Zone3: The remainder of the retina. This is crescent-shaped zone that largely involves temporal retina.



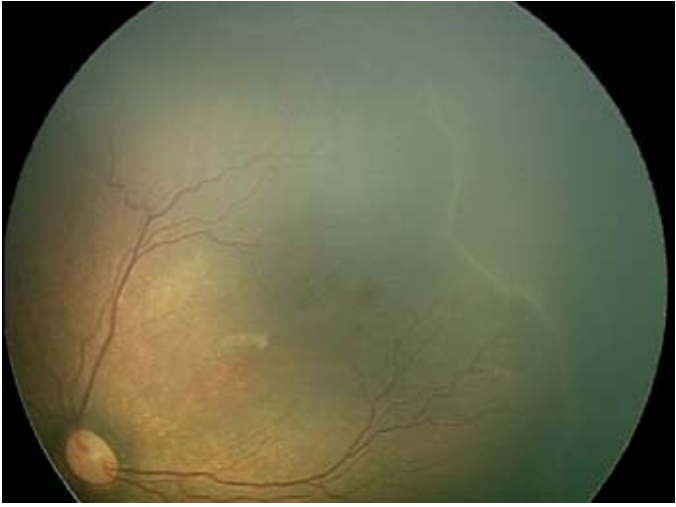


Immature retina (temporal avascular retina at zone 2)


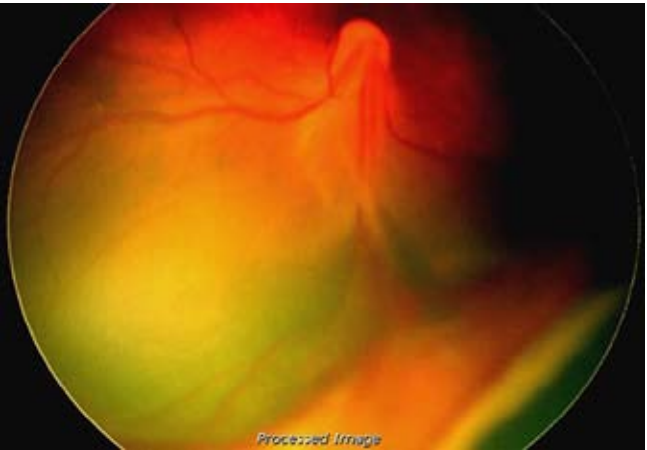
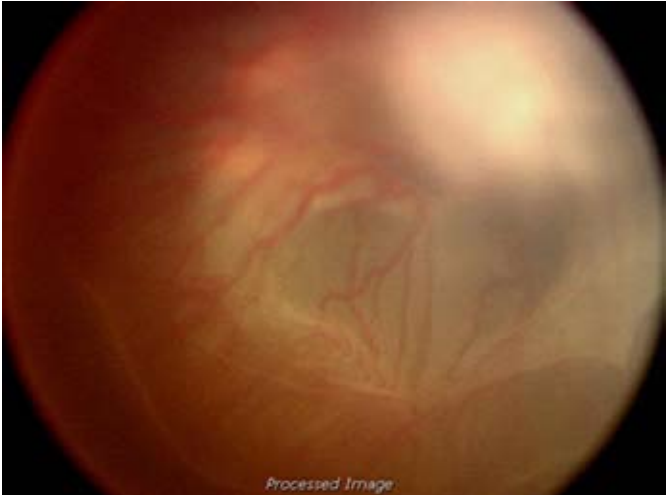


ROP at zone 2

2.2 Disease severity (Staging)

- Vascularization of the retina is incomplete or immature prior to the development of ROP.
- Disease severity is determined by staging. More than one stage may be present in the same eye.

<p>Stage 1. Demarcation line</p>	<ul style="list-style-type: none"> • A thin but definite structure separating the avascular retina anteriorly from the posteriorly vascularized retina. 	 <p>Stage 1 ROP (demarcation line)</p>
<p>Stage 2. Ridge</p>	<ul style="list-style-type: none"> • A ridge arising from the demarcation line which has 3 dimensions (height and width) and extends above the retina. 	 <p>Stage 2 ROP at zone 2 posterior</p>
<p>Stage 3. Extra retinal fibro vascular proliferation</p>	<ul style="list-style-type: none"> • Extra retinal fibrovascular proliferation or neovascularization extends into the vitreous from the ridge. • The posterior aspect of the ridge appears irregular as the proliferation becomes more extensive. 	 <p>Stage 3 ROP at zone 1</p>

<p>Stage 4. Partial retinal detachment</p>	<ul style="list-style-type: none"> Retinal detachments are generally concave and most are circumferential. 	 <p>Stage 4A ROP with Nasal Retinal Detachment</p>
	<ul style="list-style-type: none"> They are divided into 2 stages: <p>4A: extrafoveal, and</p>	
	<p>4B: foveal</p>	 <p><small>Processed Image</small> Stage 4B ROP.</p>
<p>Stage 5. Total retinal detachment</p>	<ul style="list-style-type: none"> Retinal detachments are generally tractional but may occasionally be exudative. They are usually funnel-shaped. 	 <p><small>Processed Image</small> Stage 5 ROP.</p>

Note: Some ophthalmologists use the terminology “Stage 0” to indicate that no ROP is present.

For the purposes of recording the examination for each eye, the **most severe stage** is documented with the **total extent** of all stages.

- In addition to identifying the zone, stage, and extent of the ROP, there may be other signs to indicate that the ROP is active.

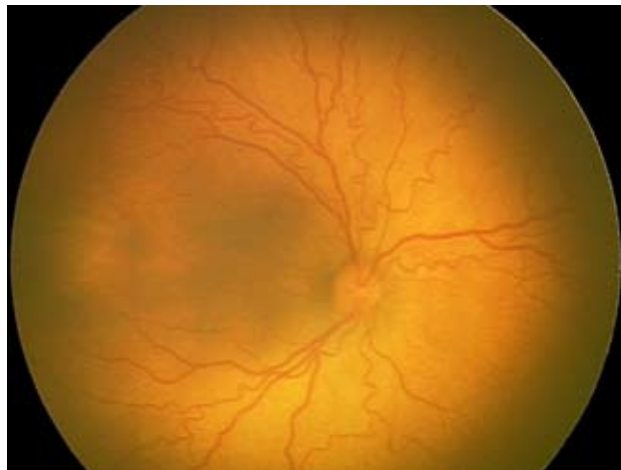2.3 Plus disease

Plus disease can be present as a major complicating factor at any stage. It is characterized by:

- Significant level of venous **dilation** and
- Arteriolar **tortuosity** of the posterior retinal vessels. This reflects the increase of blood flow through the retina
- Two **quadrants of the eye retina** must be involved for the changes to be characterized as plus disease.

Associated changes may include:

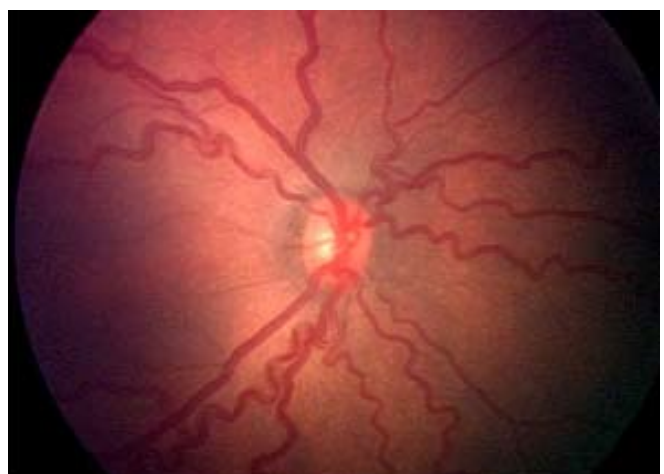- **Iris vascular engorgement**
- **Poor pupillary dilatation (rigid pupil)**
- Vitreous haze and anterior chamber haze



Plus disease: Retinal vessels are dilated and tortuous involving temporal two quadrants and thus qualifying for plus disease

Plus Disease

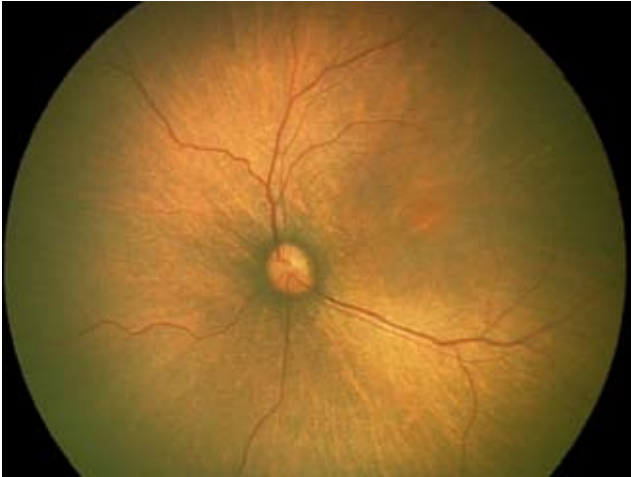- Plus disease consists of:
 - Increased venous dilatation, and
 - Arteriolar tortuosity of the posterior retinal vessels.
- Associated changes may include:
 - Iris vascular engorgement,
 - Poor pupillary dilatation (rigid pupil), and
 - Vitreous haze.
- Two quadrants of the eye must be involved for the changes to be characterized as plus disease.



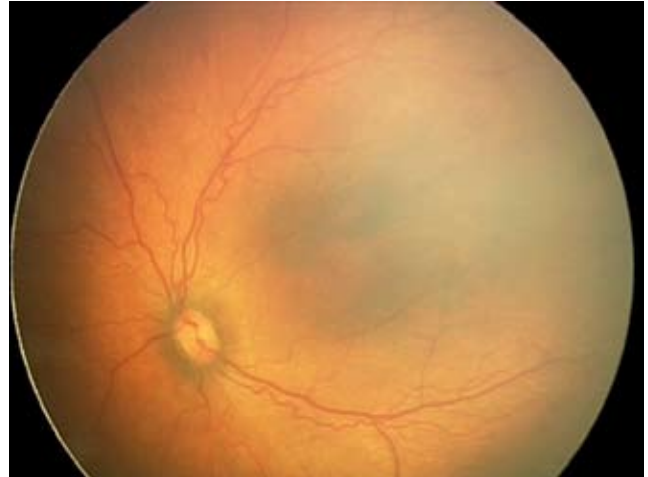Plus disease with involvement of all four quadrants

2.4 Pre-plus disease

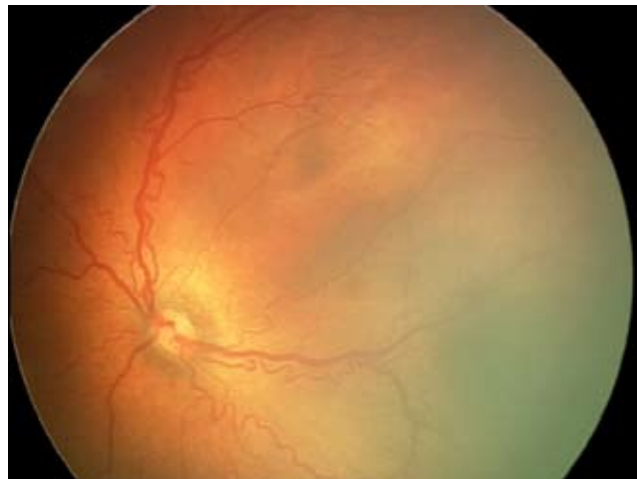1. Pre-plus disease indicates posterior pole tortuosity and dilatation that are not sufficiently abnormal to reach the criteria of plus disease, but is nevertheless greater than that regarded as normal.
2. Pre-plus disease may or may not progress to plus disease.



*Left eye with normal calibre posterior
Pole vessels*



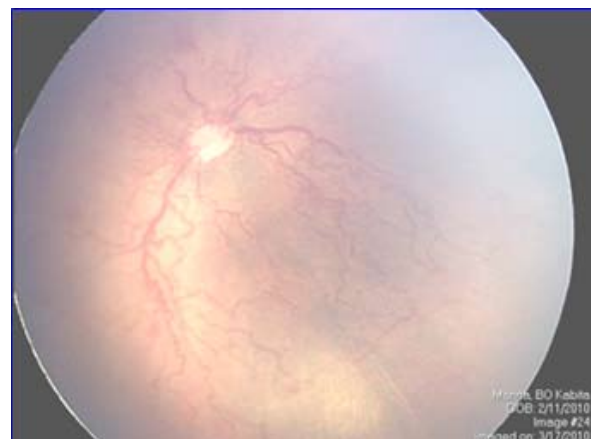
Left eye with pre-plus disease



*Same eye progressed to plus disease
in 6 days*

2.5 Aggressive posterior ROP (AP-ROP):

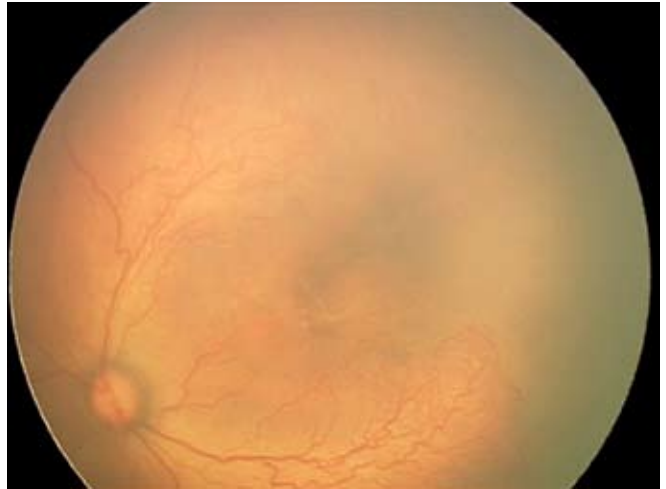A rapidly progressing, severe form of ROP, if untreated, usually progresses rapidly to stage 5 ROP. The characteristic features of this type of ROP include its posterior location, prominence of plus disease, and the ill-defined nature of the retinopathy. This may not have classical ridge or extra retinal fibro vascular proliferation, but rather have innocuous looking retina and tortuous vessels forming arcades. This type of ROP is likely to get missed by inexperienced examiners. Observed most commonly in Zone I, it may also occur in posterior Zone II.



This is an example of APROP at Zone 1

Aggressive, Posterior ROP (AP-ROP)

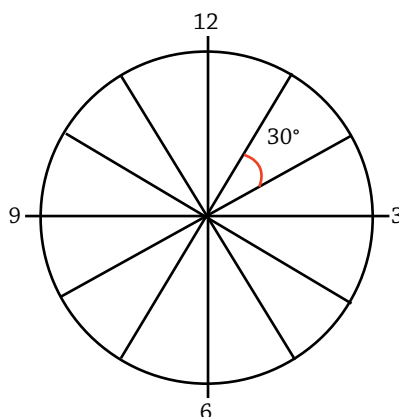
- a. This is an uncommon, rapidly progressive, and severe form of ROP that has previously been referred to as “Rush disease”. It usually occurs in the smallest, most immature infants.
- b. Untreated, it usually progresses to Stage 5 ROP.
- c. Characteristic features are:
 - the posterior location,
 - prominence of plus disease, and
 - The ill-defined, mild-appearing, and easily over-looked retinopathy at the junction between the avascular and vascular retina.
- d. It is typically circumferential and is often accompanied by a circumferential vessel.
- e. It may be difficult to differentiate between arterioles and venules because of significant dilatation of both vessel types.
- f. Hemorrhages may be present at the junction between vascularised and avascular retina.
- g. It may not progress through the classic stages 1-3 before retinal detachment occurs. It may appear as a flat network of neovascularisation at the junction between vascularised and avascular retina.
- h. Indirect ophthalmoscopy using a 20-D condensing lens instead of a 25-D or 28-D lens may assist with determining the presence of the featureless neovascularisation characteristic of AP-ROP.



Aggressive Posterior ROP.

2.6 Disease extent

- Disease extent is recorded as clock hours 1-12 hours or as twelve 30° sectors or 360°
- The clock hours recorded is the total clock hours involved, not just the contiguous sectors.



Recorded as clock hours 1-12 hours

3. RISK FACTORS FOR ROP

Various risk factors contribute to the development of ROP. They are:

- Prematurity
- Low birth weight
- High exposure to Oxygen for prolong period
- Apnoea
- Sepsis
- Anemia
- Cardiac defects
- Multiple blood transfusion
- Respiratory distress syndrome

Birth weight and gestational age – most important risk factors for development of severe ROP

- Infants with very low birth weight are at significantly higher risk of developing severe ROP that requires treatment. Similarly, the severity of ROP is inversely proportional to gestational age. Present evidence shows that low birth weight and gestational age are the most predictive risk factors for the development of ROP .

3.1 Oxygen use

Oxygen therapy has been previously implicated in the aetiology of ROP. The use of supplemental oxygen neither caused progression of pre-threshold ROP nor significantly reduced the number of infants requiring peripheral ablative therapy.

Recent evidence suggests that repeated hypoxic and hyperoxic episodes may be an important factor in the pathogenesis of ROP. Strict management of oxygen delivery without fluctuations and proper monitoring may be associated with decreased occurrence of ROP. Although the exact relationship between oxygen therapy and ROP is currently not well established, oxygen therapy seemed to play an important role in the pathogenesis of ROP.

3.2 Light exposure

- There is no evidence that light exposure is a risk factor in the development of ROP, since reduction in ambient light exposure has not reduced the incidence of ROP in high risks infants.

3.3 Other risk factors

The other risk factors that have been implicated in the development of ROP include anaemia, poor weight gain, blood transfusion, respiratory distress, breathing difficulties and the overall health of the infant. There is active research into the correlation of levels of growth factors in the blood and ROP. Close monitoring has decreased the impact of oxygen use as a risk factor for development of ROP. In addition, ROP has also been associated with intra-ventricular haemorrhage, ante-natal blood loss requiring blood transfusions and surgery under general anaesthesia, sepsis candidemia, carbon dioxide tension, raised serum bilirubin levels, and assisted conception.

- However, there is insufficient evidence to determine the degree of importance of these risk factors in contributing to the pathogenesis of ROP.

In general, other risk factors are surrogate markers of sickness in the baby. Therefore, sicker the baby higher is the risk.

4. SCREENING FOR ROP

4.1 Whom to screen

Screening should be carried out for the infants with **either** of the following:

1. Birth weight less than 2000 gm
2. Gestational age less than 34 weeks
3. Gestational age between 34 to 36 weeks but with risk factors such as: a) Cardio-respiratory support, b) Prolonged oxygen therapy, c) Respiratory distress syndrome, d) Chronic lung disease, e) Fetal hemorrhage, f) Blood transfusion, g) Neonatal sepsis, h) Exchange transfusion, i) Intraventricular haemorrhage, j) Apneas, k) Poor postnatal weight gain.
4. Infants with an unstable clinical course who are at high risk (as determined by the neonatologist or paediatrician).

4.2 When to screen

- Should receive **first screening at 4 weeks of birth.**
- Infants with period of gestation **less than 28 weeks** (gestation age) or less than 1200 grams birth weight should be first screened at **2-3 weeks after delivery.**

Post Menstrual Age (PMA) in weeks: gestational **age** plus chronological **age**.

To calculate first know at what age was he/she born in terms of completed weeks and days. Multiply by 7 to convert into days. Then add total length of stay till date and then divide by 7.

An inborn infant with Gestational Age (GA) of 32 weeks, 3 days, is discharged home from the hospital after 23 days (Initial Length Of Stay (LOS) = 23 days). Note that Initial LOS equals Total LOS for infants who are not transferred.

GA Weeks x 7 = 32 x 7 =		224 days
GA Days	+	3 days
Total LOS	+	23 days
		250 days
PMA = 250 / 7 = 35.7 Weeks		

Another method is: write the current date: MM/DD/YYYY

Then write the estimated date of delivery: MM/DD/YYYY

Current Gestational age is calculated by:

- Progression of ROP follows a distinct timeline as per Post Menstrual Age (PMA) rather than Post Natal Age (PNA) of the infant.
- **In Indian context**, ROP may be detected even before 32 weeks of PMA. However, ROP usually does not manifest before 2-3 weeks of PNA.
- The median age at detection of stage 1 ROP is 34 weeks.
- Threshold ROP appears at 34 to 38 weeks.
- **Vascularization is normally completed by 40 weeks of gestation.**

To simplify, ROP screening should be done at 4 weeks after birth. However, if any baby was delivered earlier than 28 weeks of gestation or birth weight less than 1200 gm should have a ROP screening at 2-3 weeks after birth.

4.3 Duration and frequency of screening

Initial examination

- The protocol at the participating center will determine the timing of the initial diagnostic examination.
- In general, the screening examinations will continue **at least every two weeks** until:
 - Vascularization of the retina reaches normal completion, or
 - Until ROP regresses, or
 - Until ROP requiring treatment develops.

4.4 Preparation

Personnel to carry out screening:

- A team should be constituted consisting of **District Ophthalmologist/Visiting Trained Ophthalmologist** along with **one Doctor** and **one nurse** from the **SNCU** and **Optometrist** from **DEIC**.
- Medical personnel sufficiently trained in ROP screening should perform the examination. Preferably the team should comprise an experienced ophthalmologist, medical officer and a nurse especially of the SNCU. The **ophthalmologist** has to be nominated by district hospital to visit SNCU at least once a week. One **medical officer** and one **nurse** from the **SNCU** have to be made accountable for screening of ROP. The **Optometrist** from the **DEIC** will visit the SNCU daily and would ensure screening and follow up of the at risk children. He/she would further maintain linkages with both the Ophthalmologist and the parents/guardian.
- Integrate ROP screening and management services with “National Programme For Control of Blindness” (NPCB).

4.5 Place of examination

- Neonates are best examined in the neonatal unit itself under supervision of attending paediatrician/neonatologist. It is not wise to transport small babies to ophthalmic outpatient or ward for examination. Place should be warm enough and clean. If babies are being screen at Ophthalmologist’s office, there should be arrangement for basic resuscitation equipment.
- Babies who are admitted at NICU and critically ill should be screened at NICU in presence of neonatologist **monitored by pulse oximeter**.

4.6 Equipment checklist

Screening can be carried out using the following instruments:

- Indirect ophthalmoscope preferably wireless one
- With a 20, 28 or 30 D lens (28D or 30D lens are usually preferred as they allow easier viewing of the peripheral retina)

- Paediatric speculum (Alfonso speculum)
- Infant scleral depressor
- Dilator eye drops (a) Tropicamide 0.5% b) Phenylephrine 2.5% (c) Cyclopentolate 0.5%
- Topical anaesthetic eye drop (proparacaine 0.5%)
- Topical antibiotic eye drop e.g. ciplox
- Sterile cotton and gloves
- ROP documentation sheet
- Pamphlets regarding ROP
- Optional: Wide field Digital camera
- Nesting (wrapping) of infants can significantly reduce the stress during screening procedure

Available pharmaceutical preparations of Eye drops

- Combination of Phenylephrine (5%), Tropicamide (0.8%) - This should be diluted 1: 1 with pharmaceutically available methyl cellulose eye drops, so that the final drop has 2.5% Phenylephrine and 0.4% Tropicamide. Because of the easy availability of this combination at some places, some centers prefer this combination the most.
- Tropicamide (1%) - This should be diluted 1: 1 with pharmaceutically available methyl cellulose eye drops, so that the final drop has 0.5% Tropicamide.
- Cyclopentolate (1%) - This should be diluted 1: 1 with pharmaceutically available methyl cellulose eye drops, so that the final drop has 0.5% Cyclopentolate.
- Phenylephrine (5%) - should be diluted 1:1 with pharmaceutically available methyl cellulose eye drops to obtain final concentration of 2.5%. Can be used in combination with Tropicamide 0.5% or 0.5% Cyclopentolate.

***Tropicamide** is an antimuscarinic drug that produces short acting mydriasis (dilation of the pupil) and cycloplegia when applied as eye drops. It is used to allow better examination of the lens, vitreous humor, and retina. Due to its relatively short duration of effect (4–8 hours), it is typically used during eye examinations such as the dilated fundus examination. Required for new-born 0.5%.

***Cyclopentolate** is a medication commonly used during paediatric eye examinations that dilates the eye (mydriatic), prevents accommodation of the eye to different distances (cycloplegic), and blocks specific receptors called muscarinic receptors (muscarinic antagonist). The drops take around 30–60 minutes to work and usually less than 24 hours to wear off. Required for new-born 0.5%.

***Phenylephrine (5%)**: needs to be diluted to 2.5%. Can raise the BP.

Instruments need to be clean and sterile



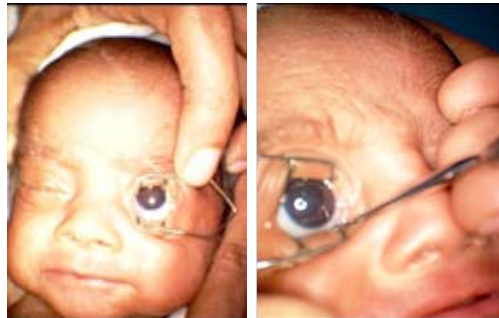Alfonso infant wire speculum



Scleral depressor (wire Vectis)



Binocular Indirect Ophthalmoscope

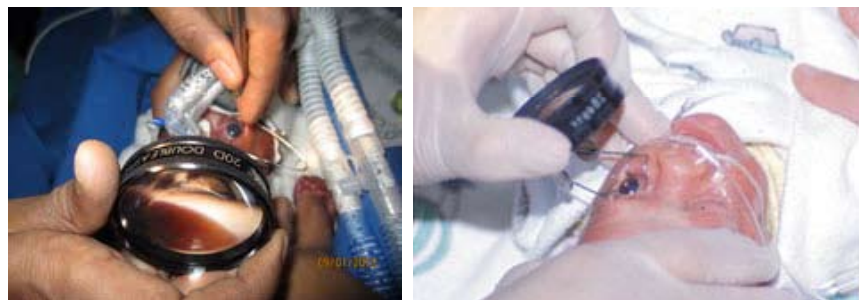

20D aspheric bi-convex lens



Laser console with indirect ophthalmoscope

ROP screening procedure (with CPAP in place)



4.7. Screening procedure

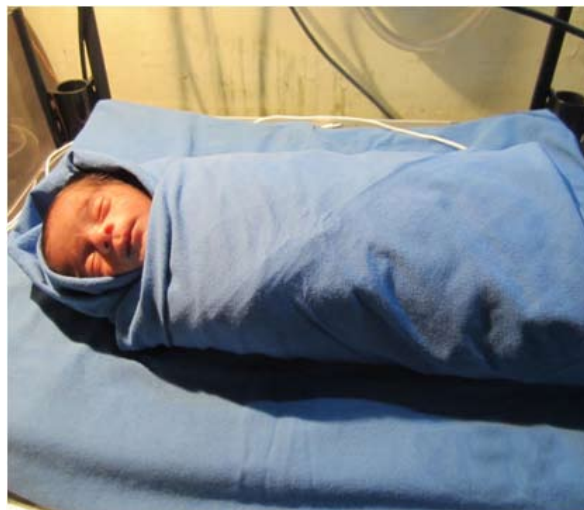a) Minimizing risk to the baby

- The examination is done after dilation of the pupils, using lid retractors and scleral depression as needed, and this may increase systemic instability of the baby.
- Special attention should be given to the possibility of bradycardia, arrhythmia, asystole, hypoventilation, apnea, or aspiration.
- Seizures have extremely rarely been reported and feeding intolerance might be present in some babies after the examination, due to the dilating drops.

- Therefore, each baby will be monitored with a member of the NICU staff present during the examination.
- To avoid transmission of conjunctivitis from one baby to another, a separate sterile speculum to be used for each baby after proper handwashing.
- Use of sterile instruments is required for each examination and hand washing or changing of gloves is required between examinations.

b) Infant physiological monitoring

- Before the examination is initiated, the sick baby will be connected to a pulse oximeter.
- If, at any time during the eye examination, the infant develops significant bradycardia or severe oxygen desaturation, the examination may need to be interrupted until the variables return to the baseline range and the baby recovers.



Proper wrapping of baby during screening or laser procedure

c) Procedure for the diagnostic eye examination

The examination procedure is as follows:

1. Baby should be well clothed and wrapped. Baby should receive a feed and burped an hour before screening.
2. Pupil should be dilated 30 minutes before examination.
3. Informed consent should be obtained from parents.
4. The baby is swaddled and arms restrained to minimise general movements and an assistant positions the baby for the examination.
5. Topical anesthetic drop proparacaine 0.5% should be applied at conjunctival sac.
6. After instillation of topical anesthesia, a sterile wire lid speculum and scleral indenter for eye rotation may be used. Pediatric speculum should be applied 30 seconds after anesthetic drop.
7. The use of oral sucrose may be considered to help with analgesia.
8. The lid speculum is inserted beneath the lid margins.
9. Screening should be done by an ophthalmologist trained in ROP screening.

d) Examination procedure:

1. First anterior segment examination to be done with condensing lens focusing on cornea, iris and lens to note any media opacity, tunica vasculosa lentis, dilated iris vessels and extent of pupillary dilatation.
2. Retinal examination to be done with indirect ophthalmoscopy using 20D/28D lens. Posterior pole as well as 360 degree peripheral retina should be examined.
3. Sclera depression to be done with wire vectis or specially designed pediatrics depressor if required.
4. Findings to be recorded according to international classification of ROP (ICROP) guidelines. Brief findings to be recorded and provided to parent with clear instruction to adhere strictly to follow up schedule. A pamphlet regarding ROP to be given to all parents.
5. One drop of antibiotic drop to be instilled in each eye at the completion of examination.
6. Baby should be observed for 15 minutes before handing over to parents.
7. Infant with ROP not amenable to laser photo-ablation (stage 4 and stage 5) should be referred to tertiary center for surgical intervention.

e) Recap of the procedure

The following steps are used to determine the status of the eye:

Step 1:

The examining ophthalmologist will examine the posterior pole, and determine the following:

- The presence or absence of plus disease (defined as two or more quadrants of vascular dilation and tortuosity using standard photographs of plus disease for reference).
- If plus disease is not present, the presence or absence of pre-plus disease using standard photographs of pre-plus disease for reference.

Step 2:

The examining ophthalmologist will then examine the remainder of the retina to determine and document the stage, zone and extent of ROP if present.

- Scleral depression is used as needed to visualize the entire fundus out to the ora serrata.
- Particular attention is given to area of scleral indentation, but also adjacent to it to detect peripheral ROP that may be posterior to the downslope of the indentation.
- Each quadrant is examined and the findings are recorded using the ICROP system.

f) Recording the findings in the screening form

- Use of a standardized form using the ICROP zones is encouraged but not mandatory.

Documentation will include:

- the zone of vascularisation,
- the stage of ROP,

- the extent of ROP (in clock hours)
- the presence of plus, or pre-plus, disease,
- the presence of AP-ROP,
- Whether treatment is indicated, and
- When follow-up is planned.

g) Precautions to be taken during screening

- ROP screening examination can have short-term effects on blood pressure, heart rate and respiratory function in the premature baby.
- The examination should be kept as brief as possible and precaution is taken to ensure that emergency situations can be dealt with promptly and effectively.
- Discomfort to the baby should be minimized by administering oral sucrose just before examination.
- Pretreatment of the eyes with a topical proparacaine and swaddling the baby.
- Baby should not be fed just before examination to avoid vomiting and aspiration.
- Hand hygiene should be practiced to maintain asepsis.

h) Dilating regimen: How to dilate?

- **Tropicamide eye drops:** 0.5% with phenylephrine 2.5% or cyclopentolate 0.5% with phenylephrine 2.5% eye drops - one drop three times at 10 minutes interval. Need to dilute commercially available combination dilator (Tropicamide 0.8% with phenylephrine 5%) drop with methyl cellulose eye drops or distilled water. Pupil usually dilates in 30 minutes time and it persists for 30 to 45 minutes. To avoid excessive absorption and toxicity wipe the excess drops from medial canthus after putting the drop in the infants eye especially when baby is lying in supine position either on the mother's lap or on the bed.
- **Cyclopentolate eye drops:** 0.5%. It will help to keep the pupil dilated longer time specially when Laser is planned.

Practice tip: *If pupils are not dilating despite administration of adequate mydriatic drops, severe or advanced ROP should be suspected.*

Use of improper eye drop or undiluted eye drop can prove fatal for the baby

- To produce adequate dilation for examination, both cyclopentolate 0.5% and phenylephrine 2.5%, should be employed, one drop to each eye at two different times. The interval between applications will be 10 minutes.
- In those few babies for whom this dilating regimen proves inadequate, additional 1-2 drops of cyclopentolate 0.5% and 1 drop of phenylephrine 2.5%, can be used for each eye.
- For babies known to have systemic hypertension, the use of phenylephrine should be minimized.
- Topical ophthalmic anesthesia (tetracaine 0.5% or proparacaine) is instilled in both eyes at the discretion of the ophthalmologist.

Screening of all infants at risk of developing ROP should be continued regularly until:

- Retina is completely vascularised.
- ROP has fully regressed and there are no signs of risk for visual loss. This normally happens at around 40-42 weeks of PMA.
- ROP has progressed to a level of severity where treatment is indicated.

The following are the recommended follow up intervals for the infants at risk.**1. No signs of ROP:**

Follow up examination for infants at risk should be done 2-3 week intervals until the retina is fully vascularised.

2. If ROP is present:**Zone 1:**

Stage 1, 2 or 3; **ROP without plus disease** should be **screened at least weekly** because there is a high risk of disease progression (treatment would be required in plus disease irrespective of the stage i.e., 1, 2 or 3).

Zone 2

1. Immature vasculature should be **screened once in 2-3 weeks.**
2. Zone 2 stage 1 ROP should be **screened once in 2 weeks.**
3. Zone 2 stage 2 ROP without plus should be **screened once in 1-2 weeks.**
4. Zone 2 stage 3 ROP without plus should be **screened at least weekly.**

If there is pre-plus disease, baby should be screened at 3-4 day interval.

Zone of retinal findings	Stage	Follow up interval
Zone 1	Immature vasculature	1-2 weeks
	Stage 1 or 2	1 week or less
	Regressing ROP	1-2 weeks
Zone 2	Immature vasculature	2-3 weeks
	Stage 1	2 weeks
	Stage 2	1-2 weeks
	Stage 3	1 week or less
	Regressing ROP	1-2 weeks
Zone 2	Stage 1 or 2	2-3 weeks
	Regressing ROP	2-3 weeks

5. MANAGEMENT OF ROP

The principle of treatment is to remove the stimulus for growth of new blood vessels by ablating the peripheral avascular retina. This will in turn reduce the incidence of retinal detachment and consequent blindness. The treatment involves ablation of peripheral avascular retina and thereby abolishing hypoxic drive of retina (mediated by over-expression of vascular endothelial growth factor; VEGF). This results in regression of established ROP.

5.1 Timing and Place of Treatment

5.1a Timing

When indicated, treatment should be carried out as soon as possible, ideally within 2-3 days of the diagnosis. However treatment is warranted within 48 hours of diagnosis of classical form of disease and as soon as possible in APROP. The rationale is that the disease can advance rapidly and any delay in treatment will reduce the chances of success.

5.1b Place of laser treatment

This has to be preferably performed in NICU/SNCU monitored by neonatologist or paediatrician. Alternatively in a stand-alone Eye Hospital, laser treatment could be performed in an operation theatre monitored by an experienced anesthesiologist with experience in handling newborn babies.

5.2 Type of treatment:

1. **Laser therapy**

Laser therapy is the procedure of choice, being less invasive, less traumatic to the eye and causes less discomfort to the infant. Laser is also simpler to apply in treating posteriorly located disease. Both double frequency Nd-YAG laser and Diode red wavelengths laser can be delivered through an indirect ophthalmoscope. Laser burns should be **applied on the entire peripheral avascular retina anterior to the ridge, excluding the ridge**. Ideally, laser applications should be spaced one half burn-widths apart. Better results were documented with near confluent burn. **Additionally, 'laser spots'** on retina are visible during the procedure minimizing the skip areas requiring re-treatment. The procedure can be carried out under topical anesthesia with or without sedation.

Complications of laser therapy:

Laser treatment may cause burns in cornea and iris. Other complications include cataract, and retinal and vitreous haemorrhage. Ocular ischemic syndrome, angle closure glaucoma, inadvertent damage to the vascularised retina including macula.

2. **Cryotherapy**

Cryotherapy significantly improves the outcome of severe ROP. This has been largely superseded by laser photocoagulation due to its higher incidence of treatment related complications.

Complications of cryotherapy

Cryotherapy can result in ocular complications like eyelid oedema, laceration of the conjunctiva, and pre-retinal and vitreous haemorrhage as well as systemic complications like bradycardia, cyanosis and respiratory depression.

3. **Treatment of advanced disease**

Neither cryotherapy nor laser photocoagulation is successful in all cases of advanced disease. Despite meticulous management there may be serious sequelae. Such cases should be referred to centers dealing with advanced retinal surgery.

5.3 Aim of treatment

The aim of treatment is to reduce the incidence of retinal detachment and blindness

The ET-ROP (Early Treatment for ROP) study demonstrated improved visual outcomes with earlier laser treatment and has replaced previous guidelines set by the CRYO-ROP study.

5.4 Indications for both active peripheral retinal ablation and passive waiting for progression/regression

Treatment of ROP is based on differentiation of following two types of ROP:

Type 1 ROP: Administer peripheral ablation treatment

- Zone I, any stage ROP with plus disease
- Zone I, stage 3 ROP without plus disease
- Zone II, stage 2 or 3 ROP with plus disease

Type 2 ROP: Wait and watch for progression/regression

- Zone I, stage 1 or 2 ROP without plus disease
- Zone II, stage 3 ROP without plus disease

5.5 Laser in ROP

Laser to be done by ophthalmologist trained in ROP laser. It should be performed at SNCU/NICU only in presence of neonatologist with pulse Oximetry monitoring. If required laser can be applied through sloped incubator wall.

5.6 Equipment's required for laser procedure:

1. Laser console –810 nm diode laser or 532 nm green laser
2. Indirect laser delivery system
3. A pair of laser protective glasses
4. All equipment required for ROP screening

5.7 Indications of laser procedure:

1. Currently laser is the standard treatment for ROP. Laser is to be done according to the ETROP guidelines.
2. Once decided laser is to applied within 48 hours of diagnosis.
3. If the diagnosis is aggressive posterior ROP (APROP) laser is to be done as soon as possible and confluent laser burn to be applied to whole of avascular retina.

5.8 Laser procedure:

1. Informed consent to be taken from parents before the procedure.
2. Oral feeds should be discontinued 1 hour prior to the procedure.

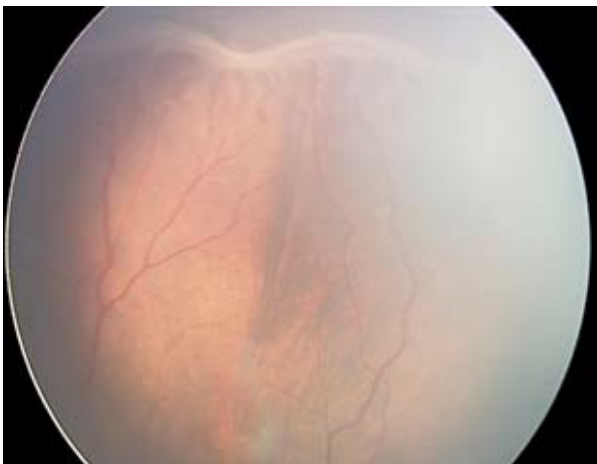3. Baby should be put on cardio-respiratory monitor and if large area of retina needs to be ablated like in Zone I and Zone 2 posterior disease I.V. fluid should be started. Dilatation of pupil is ensured by using tropicamide 0.5% and phenylephrine 2.5% or cyclopentolate 0.5% and phenylephrine 2.5% eye drops can be used to have pupillary sustained dilatation for laser photoablation.
4. Can be done under topical anesthesia to avoid systemic side effects of general anesthesia or sedation.
5. 24% dextrose solution can be given orally to minimize the pain during the procedure.
6. If required general anesthesia or sedation can be used.
7. Precaution to be taken to prevent hypothermia, hypoglycemia during and after the procedure
8. Both the eyes can be treated at the same sitting unless contraindicated by instability of the baby.
9. Vitals to be monitored during and for 2 hours after the procedure.
10. Oral feed to be given 30 minutes after procedure.
11. If baby is not tolerating the procedure, consider abandoning the procedure for the time being. Vital signs and oxygen saturation should be monitored very closely.
12. Premature babies, especially those with chronic lung disease may have increased or re-appearance of apneic episodes or an increase in oxygen requirement. Therefore they should be carefully monitored for 48-72 hours after the procedure.

5.9 Post laser care : follow up

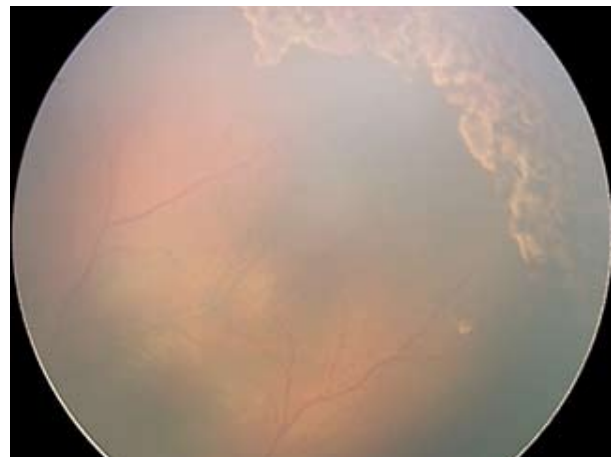Topical antibiotics and steroid to be prescribed three times a day for 7 days. There is increased risk of hyphaema, posterior synechiae and transient cataract in very premature babies specially those with APROP requiring large number of laser burns. Topical mydriatics may be added for one week in few cases of APROP but is not a routine practice.

5.10 Post laser examination and re-treatment

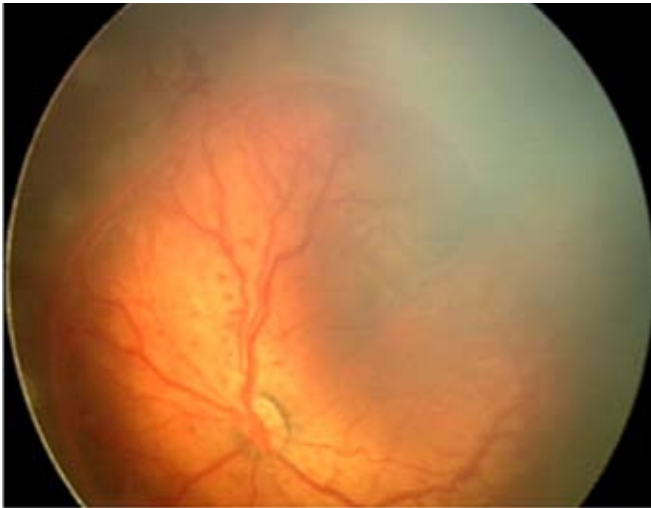The purpose of the post laser examination is to determine whether re-treatment is necessary and to monitor the disease regression. After laser therapy first examination to be done 5 to 7 days after treatment and should be continued at least weekly for signs of decreasing activity and regression. Re-treatment should be performed usually 10 to 14 days after initial treatment when there has been a failure of the ROP to regress. Need for long term follow up should be stressed to parents. In case of persistence of plus disease, poor regression or disease progression, referral to a higher centre should be done.



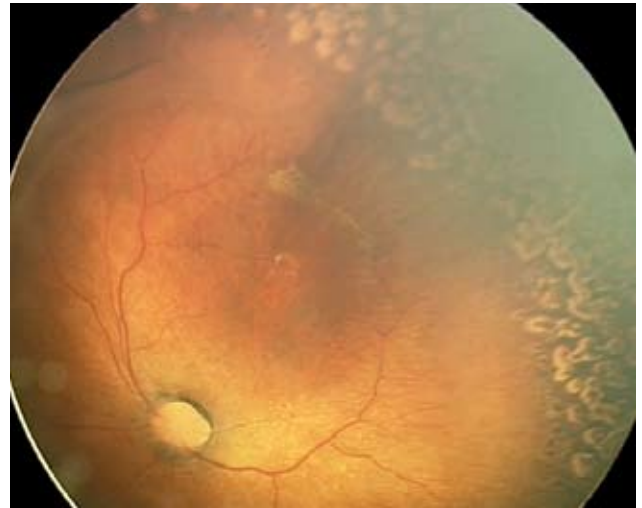
STAGE III ZONE 2 ROP RIGHT EYE



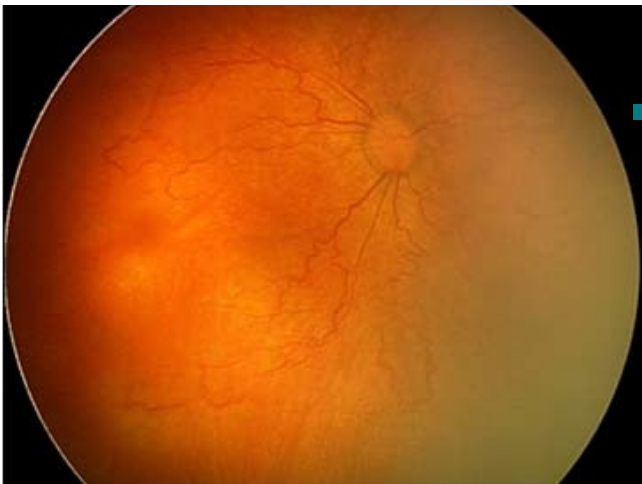POST LASER



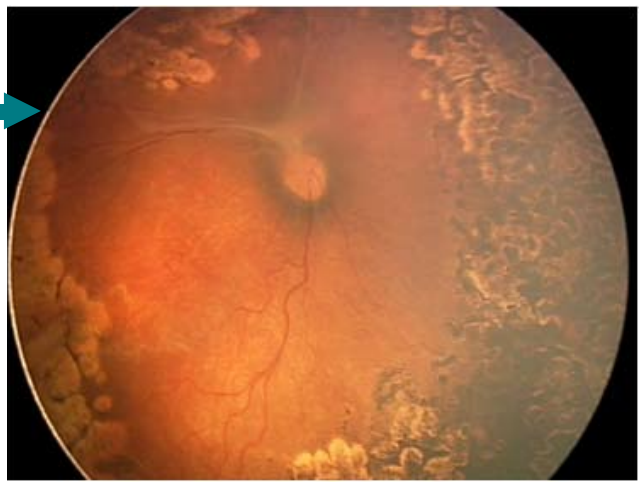
*Stage 3 ROP at Zone 2 posterior with plus disease-
pre laser*



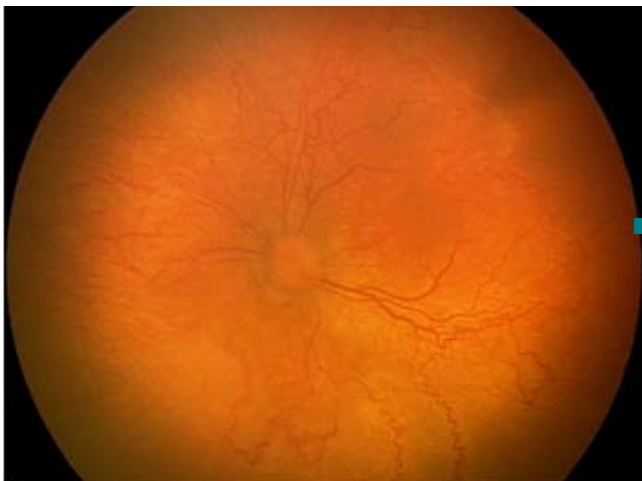Same eye after laser photocoagulation



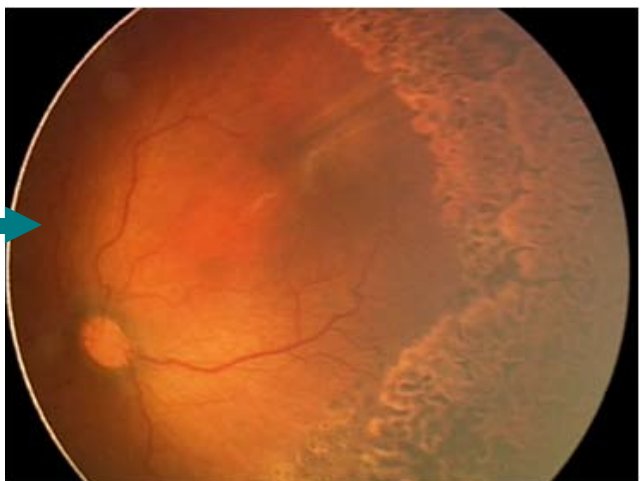
APROP pre laser



APROP POST LASER



APROP pre laser



APROP POST LASER

6. FOLLOW-UP EXAMINATIONS IN SNCU/NICU

6.1 Eyes without ROP

- An immature eye (avascular peripheral retina, no ROP) is examined at least every other week until vessels reach zone III, confirmed by two examinations approximately one week apart or until 44 weeks post-term, whichever occurs first.
- Vascularization has proceeded into zone III when vessels are observed up to the ora serrata in the two nasal clock hours of the eye.
- Examination of this portion of the retina involves scleral indentation with a scleral depressor.
- When normal retinal vasculature progression into zone III has been observed on two occasions at least one week apart, then the baby will be discharged from the ROP protocol and followed according to standard ophthalmological practice.
- There are cases with slowly maturing eyes where the vessels seem never to progress into zone III. If retinal vessels are observed to be in zone II and no ROP has developed on three successive examinations, the time between examinations can be extended while the baby remains hospitalized, and as ophthalmological indicated after discharge.

6.2 Eyes with ROP

- If ROP is observed for the first time and plus disease is not diagnosed, then follow-up examinations will be at least weekly or every other week.
- If ROP is progressing, follow-up examinations will occur at least every other week, but follow-ups will more commonly occur on a weekly or twice-weekly basis depending on the features of the retinopathy.
- If ROP is observed by the ophthalmologist to be regressing on two successive examinations, follow-up will be as indicated by the examining ophthalmologist.
- If the examining ophthalmologist determines that ROP warranting treatment is present, treatment will be delivered according to standard clinical care.

7. COMPLICATIONS OF ROP

- Myopia occurs in about 80% of infants with ROP.
- Strabismus and amblyopia are also common residual findings. The prevalence of strabismus ranges from 23% to 47% in infants with ROP and found to be 20% in a regional study.
- Retinal detachment has been seen in 22% patients. Retinal detachment can occur as early as 6 months up to 31 years from the time of diagnosis, with a mean age of 13 years in regressed ROP patients.
- Retinal detachment may even occur in sub-threshold ROP.
- Acute angle closure glaucoma can be seen in cicatricial ROP.

8. ISSUES, FOLLOW UP AND COUNSELLING

8.1 Post screening

- Assessment of vision should be carried out in all pre-term infants throughout the first year of life to detect associated disorders like neurological abnormalities and amblyopia.
- Periodic monitoring of visual acuity is also carried out since severe ROP may be associated with impaired visual development.

8.2 Children treated for ROP

- Follow-up examinations should be tailored individually.
- If adequate laser/cryotherapy treatment has been given, and the disease has fully regressed, a follow-up examination should be carried out at 3 months.
- Cycloplegic refraction should be performed at 6 months.
- Follow-up should be annually. Sometimes more frequent follow up is necessary if indicated.

Post treatment follow-up should be carried out for all infants till they reach pre-school years, to monitor the development of vision, refractive status and strabismus.

8.3 Children with complications of ROP

Ophthalmologist must ensure that the child gains early access to the services for the visually impaired. The social and educational services provide much needed support to these children.

8.4 Counselling

Counselling of the parents is essential depending on the severity of the disease

- **Parents of all babies at risk** - written general information should be provided
- **Parents of infants with severe ROP** - the ophthalmologist should personally discuss about the disease and availability of management with the parents.
- **Parents of infants with advanced cicatricial ROP and with visual impairment** – It is important to ensure that children with visual impairment have access to all services, registration with relevant associations of the blind and vocational guidance centers.

9. OTHER MODALITIES OF TREATMENT

Anti-VEGF drugs

- Intravitreal injection of anti-VEGF drugs has been demonstrated to diminish the neovascular response significantly in animal models and human studies.
- Studies reveal intravitreal bevacizumab monotherapy (Anti-VEGF drugs) showed a significant benefit for zone I disease (and APROP) but not zone II disease when used to treat infants with stage 3+ retinopathy of prematurity.

- Potential benefits of intravitreal Avastin injection over laser therapy include: reduction in level of anesthesia required, preservation of viable peripheral retina, and, possibly, reduced incidence of subsequent high refractive error.
- However, **the safety of this new treatment has not yet been established in terms of ocular complications as well as systemic complications**. The latter are theoretically possible, as the active ingredient of bevacizumab not only blocks the development of abnormal blood vessels in the eye but may also prevent the normal development of other tissues such as the lung and kidney.
- As VEGF is an important mediator of lung growth and brain development, and there is significant systemic absorption of anti VEGF medication after intravitreal injection, there are concerns regarding toxicity of such therapy.
- Due to lack of data on potentially serious systemic adverse effects **administration of intravitreal bevacizumab (anti-VEGF monoclonal antibody) is not routinely recommended in neonates with ROP**.
- It may be used only when laser photocoagulation fails and after taking informed consent from the parents; in cases of Zone I ROP where even the center of macula is not vascularised, ROP not regressing despite adequate laser as a pre-operative measure in Retinal detachment with high vascularity to reduce intra operative bleeding.

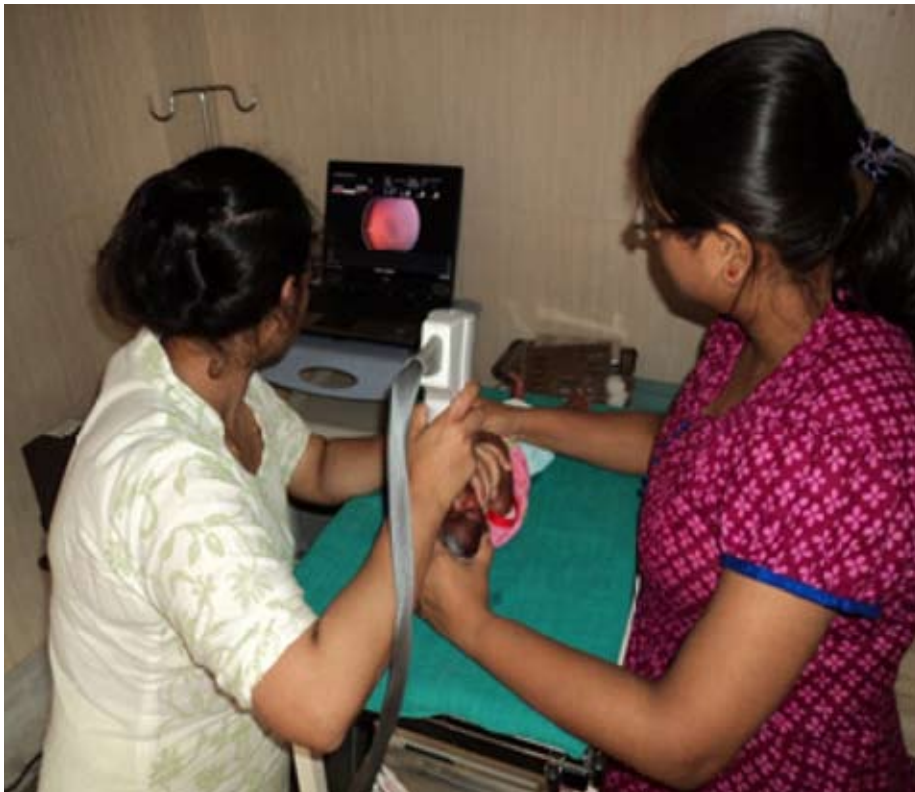Use of wide-field digital camera for screening:

A wide-field digital camera capable of retinal imaging in preterm infants has been evaluated as an alternative to Indirect Ophthalmoscope for screening. Retinal images taken by camera can be stored, transmitted to expert, reviewed, analyzed and sequentially compared over time and are useful for telemedicine purposes. **However, due to high cost and limitations in diagnostic accuracy** particularly with poor image quality, wide-field digital camera cannot replace Indirect Ophthalmoscope in current scenario. Digital fundus images acquired by Ret-Cam can serve as a useful adjunct to conventional bedside ROP screening by Indirect Ophthalmoscope.

Regional shortages in the availability of ophthalmologists to provide ROP diagnostic examinations are an important barrier to ensuring appropriate ROP care. One potential solution is to decrease the number of indirect ophthalmoscopy examinations by first screening with some other method. As affordable wide field cameras become available and validated, the usage of telescreening is expected to increase

NICUs/SNCU with poor access to experienced ophthalmologists should first attempt to improve such access by working with the local ophthalmologic community and hospital administration before adopting retinal imaging. Finally, we strongly recommend that all NICUs/SNCU that elect to adopt retinal imaging collect outcome data to expand the evidence base and monitor for any cases of potentially preventable visual impairment.

The key questions for Retinal imaging for SNCU are mainly the **costs and benefits of using retinal imaging to detect ROP**, Linking up with management for ROP, maintenance of the equipment and finally any risk associated with Retinal Camera. Till then in India: binocular indirect ophthalmoscopy examinations are recommended for infants at risk for the development of ROP. Serial diagnostic examinations are performed until each eye is considered no longer at risk for developing serious ROP (i.e., full retinal vascularization, postmenstrual age of 45 weeks, and no pre-threshold disease, zone III retinal vascularization without previous zone I or II ROP, or regression of ROP).



RETCAM SHUTTLE
WIDE FIELD DIGITAL
IMAGING SYSTEM With
all standard accessories

10. ROP RECORDING FORM

Neonatal Ophthalmology Examination Record for ROP					SNCU Data base:			
Identification	Name: Baby of	Date of birth	Birth weight	-/-/-gm.	Gestational age at time of birth	-/-/- weeks and days	Estimated day of delivery (by LMP/USG)	MM/DD/YYYY
Risk factor	Oxygen supplementation Y/N: <input type="checkbox"/> <input type="checkbox"/> <input type="checkbox"/> <input type="checkbox"/> hrs. Sepsis Y/N. Clinical/screening proven/culture proven Blood transfusion Y/N No of unit <input type="checkbox"/> <input type="checkbox"/> Multiple births Y/Order <input type="checkbox"/> <input type="checkbox"/> NEC. Y/N Apnea. Y/N: no of episodes <input type="checkbox"/> <input type="checkbox"/>				RDS.Y/N Anemia Y/N: Hb g% <input type="checkbox"/> <input type="checkbox"/> Thrombocytopenia Y/N Intra-ventricular hemorrhage Y/N, grade <input type="checkbox"/> Cardiovascular defect other than PDA Y/N. PDA Y/N maternal factor – H/o hypertension/ anemia/ assisted conception/ premature rupture of AM			

Name of the Hospital								
Current Date: MM/DD/YYYY								
EDD: MM/DD/YYYY (40 w)								
Current Gestational Age: Weeks and days								
Follow Up No.:								
Any Comments On: Cornea, Iris, lens, Pupil, Vitreous, optic nerve								
Report	Zone: 1-3	Stage: 1-5	Preplus: Y/N	Plus Disease: Y/N	Total Clock hours	APROP Y/N		
Right eye								
Left eye								
any other ocular abnormality detected	1. Lids:		2. Conjunctiva:		3. Cornea:		4. Iris:	
	5. Anterior chamber:		6. Lens:		7. Vitreous:		8. Optic nerve	
Recommendation	Follow Up/Laser ablation/referral to tertiary center for surgical intervention				Next follow up date: MM/DD/YYYY			

Follow Up Form

Name of the Hospital						
Current Date: MM/DD/YYYY						
EDD: MM/DD/YYYY (40 w)						
Current Gestational Age: Weeks and days						
Follow Up No.:						
Any Comments On: Cornea, Iris, lens, Pupil, Vitreous, optic nerve						
Report	Zone: 1-3	Stage: 1-5	Preplus: Y / N	Plus Disease: Y / N	Total Clock hours	APROP Y / N
Right eye						
Left eye						
Any other ocular abnormality detected	1. Lids:	2. Conjunctiva:	3. Cornea:	4. Iris:		
	5. Anterior chamber:	6. Lens:	7. Vitreous:	8. Optic nerve		
Recommendation	Follow Up /Laser ablation/ referral to tertiary center for surgical intervention				Next follow up date: MM/DD/YYYY	
Refraction	To be done at DEIC					

11. PREVENTIVE MEASURES

Antenatal steroids

Use of prenatal steroids is a well-known approach to prevent respiratory distress and intraventricular hemorrhage, two important risk factors of ROP. Though antenatal steroids have not reduced occurrence of ROP, perhaps because it saves smaller babies who are at higher risk of developing ROP, but, as it reduces sickness level in preterm infants, prenatal steroids are likely to reduce severe ROP.

Judicious oxygen therapy

Oxygen is a drug and it should be used judiciously. Each neonatal unit should have a written policy regarding when and how to use oxygen and target saturations.

If a preterm neonate <32 weeks gestation needs resuscitation at birth, inhaled oxygen concentration (FiO_2) should be titrated to prevent hyperoxia and achieve gradual increase in oxygen saturation (70% at 3 minute and 80% at 5 minute after birth). During acute care of a sick preterm neonate, ROP is more likely to develop if partial pressure of oxygen in arterial blood is more than 80 mm Hg.

Oxygen level in blood should be continuously monitored using pulse oximetry keeping a saturation target of 90% to 93%, with limits set at 88% and 95%. It has been observed that if oxygen saturation in a baby on oxygen therapy is kept between 85% and 93%, in about 90% samples partial pressure of oxygen is in desirable range (50 to 80 mm Hg). It is important that a work culture is inculcated wherein physicians and nurses respond to monitor alarms.

Therefore it is recommended that saturations in preterm neonates be maintained between 90% and 95%. Saturations should be monitored in preterm infants receiving oxygen therapy to prevent hyperoxia or hypoxia.

Judicious use of blood transfusions

Transfusion of packed RBCs is another risk factor of ROP. Adult RBCs are rich in 2, 3 DPG and adult Hb binds less firmly to oxygen, thus releasing more oxygen to the retinal tissue.

Packed cell transfusions should be given when hematocrit falls below following ranges:

- Ventilated infants: 40%
- Infants with cardio-pulmonary disease but not on ventilators: 35%
- Sick infants but no cardiopulmonary instability: 30%,
- Symptomatic anemia (tachycardia >180/minute or respiratory rate > 60 for \geq 24hour, doubling of the oxygen requirement in last 48 hours, lactate > 2.5 mEq/L or acute metabolic acidosis with pH <7.20 or weight gain less than 10 grams/kg/day over 4 days while receiving 120 kcal/kg/day): 25%
- Asymptomatic anemia: 20%.

Other interventions

Supplementation of high doses of Vitamin E or reduced ambient light exposure is not associated with reduced incidence of ROP. In neonates with early stages of ROP administration of supplementation oxygen to achieve oxygen saturation in supra-physiological range and to reduce retinal hypoxia is not associated with halt in progression of ROP.

12. QUALITY IMPROVEMENT

Protocol based approach

- All units caring for babies at risk of ROP should have a written protocol in relation to the screening for, and treatment of, ROP. This should include responsibilities for follow-up of babies transferred or discharged from the unit before screening is complete.
- If babies are transferred either before ROP screening is initiated or when it has been started but not completed, it is the responsibility of the consultant neonatologist to ensure that the neonatal team in the receiving unit is aware of the need to start or continue ROP screening.

- Whenever possible ROP screening should be completed prior to discharge. There should be a record of all babies who require review and the arrangements for their follow-up.
- For babies discharged home before screening is complete, the first follow-up out-patient appointment must be made before hospital discharge and the importance of attendance explained to the parents.

Auditing

Following outcomes should be regularly audited in units with ROP screening and treatment programme.

- Completeness of screening program: Percentage of eligible babies who receive at least one ROP eye examination.
- Timing of first screen: Percentage of eligible babies receiving first ROP screening exam by 4 weeks of postnatal age.
- Timing of treatment: Percentage of babies needing ROP treatment for their ROP who are treated within 48 hours of the decision to treat being made.

13. STRATEGIES FOR CONTROL OF VISUAL LOSS FROM ROP

PRIMARY PREVENTION		SECONDARY PREVENTION	TERTIARY PREVENTION
<ul style="list-style-type: none"> * Prevention of preterm birth * In situ transfer with preterm delivery in health facility with SNCU/NICU * Antenatal steroids for threatening preterm delivery * Prevention of ROP among preterm infants by high quality neonatal care from immediately after delivery and in the SNCU/NICU 		<ul style="list-style-type: none"> * Early detection of sight threatening ROP * Urgent treatment of sight threatening ROP * Follow up of treated infants 	<ul style="list-style-type: none"> * Surgery for retinal detachment due to ROP
In the delivery room <ul style="list-style-type: none"> * Gentle resuscitation in room air * Avoid ventilation * Avoid 100% supplemental oxygen * Delayed cord clamping * Maintain body temperature 	In the SNCU/NICU <ul style="list-style-type: none"> * Avoid 100% unmonitored supplemental oxygen * Prevent sepsis by hand washing * Promote feeding with breast milk * Avoid unnecessary blood transfusions * Supportive care, including swaddling and kangaroo care 		

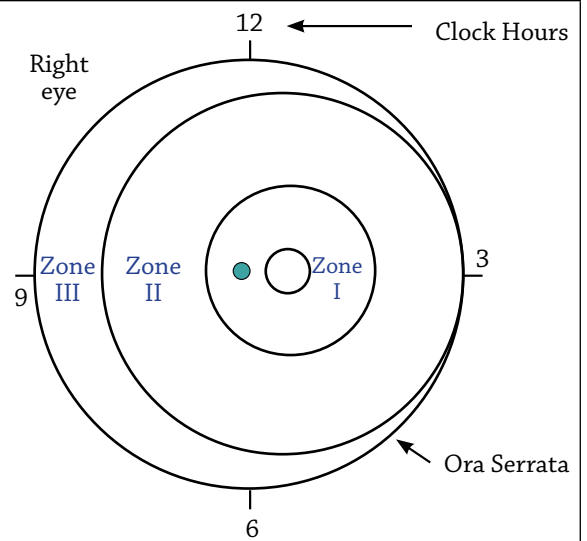
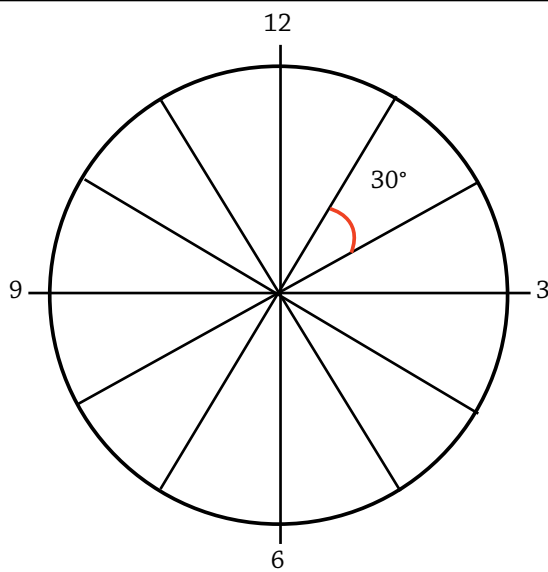
Note: Primary prevention of sight threatening ROP should be emphasised in the Facility Based Newborn Care Guidelines used by SNCUs.

14. EXERCISE ON ROP

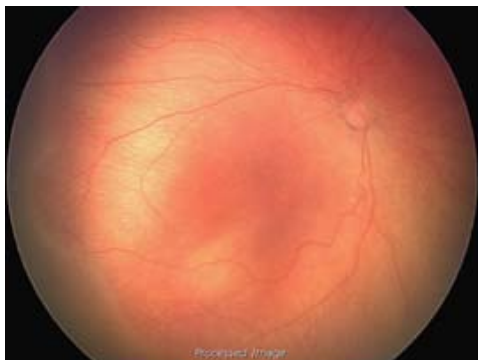For each of the image of affected eyes due to ROP, you will need to complete the details of the examination of the eye:

- Zone of vascularisation
- Stage of disease
- Presence of plus or pre-plus disease
- Presence of APROP
- Whether treatment is indicated
- The final image will allow you to assess the extent

Take help from these figures



1



Zone:

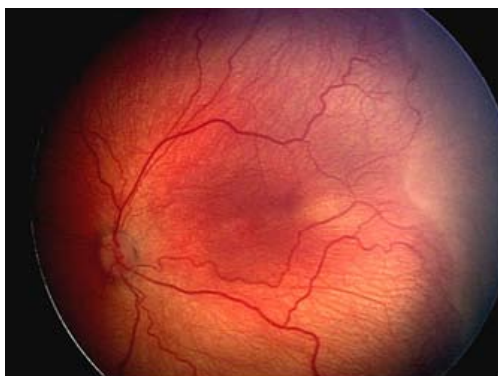Stage:

Plus disease:

APROP:

Treatment:

2




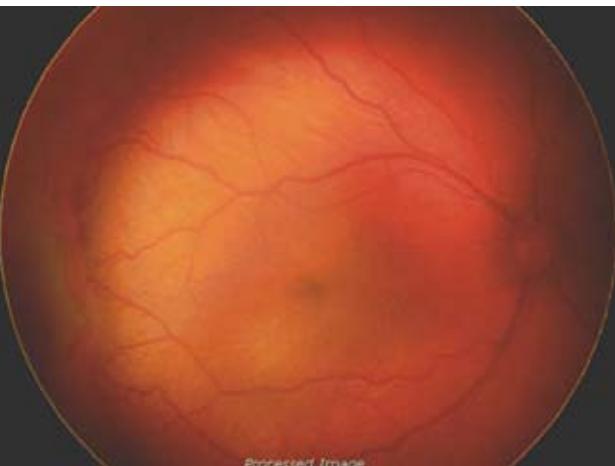


Zone:

Stage:

Plus disease:

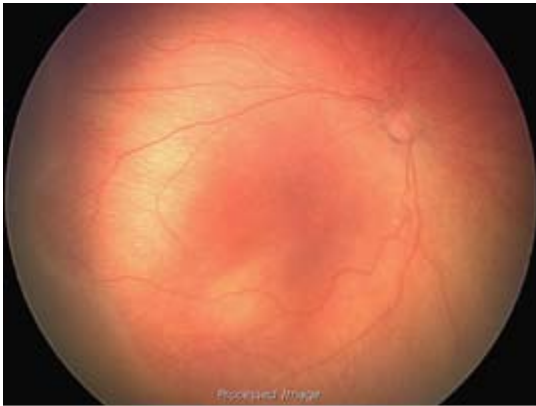APROP:

Treatment:

<p>3</p>		<p>Zone:</p> <p>Stage:</p> <p>Plus disease:</p> <p>APROP:</p> <p>Treatment:</p>
<p>4</p>		<p>Zone:</p> <p>Stage:</p> <p>Plus disease:</p> <p>APROP:</p> <p>Treatment:</p>
<p>5</p>		<p>Zone:</p> <p>Stage:</p> <p>Plus disease:</p> <p>APROP:</p> <p>Treatment:</p>
<p>6</p>		<p>Zone:</p> <p>Stage:</p> <p>Plus disease:</p> <p>APROP:</p> <p>Treatment:</p>

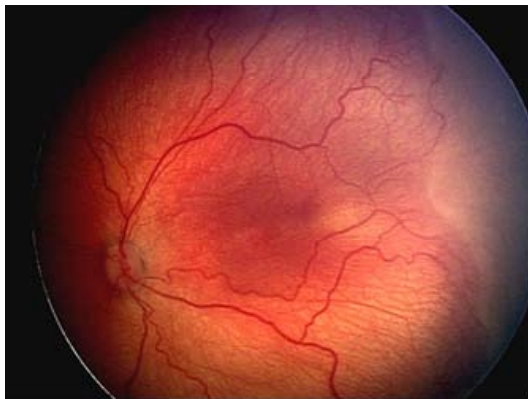ANSWERS

1



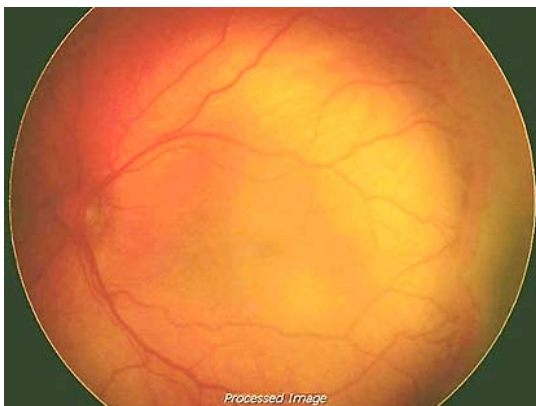This fundal image shows a clear demarcation line consistent with Stage 1 ROP. The vascularity extends into Zone II. On this image, the ROP is seen to extend for at least 4 clock hours from 7 o'clock to 11 o'clock. There is no evidence of plus disease or pre-plus disease. There is no evidence of AP-ROP. No treatment is indicated. It is recommended that the infant is reviewed in 2 weeks.

2



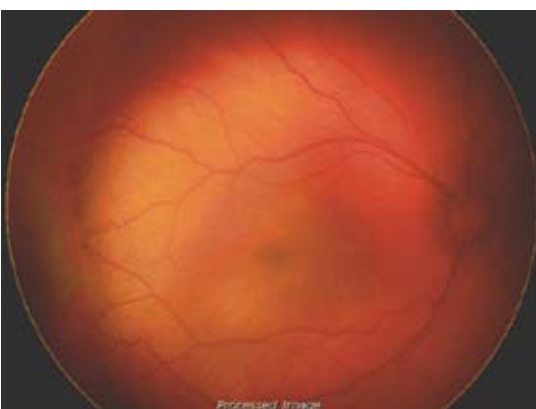This image demonstrates Stage 2 ROP in Zone II. A clear ridge is seen at the border of the vascularised and avascular retina. On this image, the ROP is seen to extend for at least 3 clock hours from 1 o'clock to 4 o'clock. There is mildly increased tortuosity of vessels, indicating the presence of pre-plus disease. There is no evidence of AP-ROP. No treatment is indicated. It is recommended that the infant is reviewed in 1 week.

3



This image demonstrates Stage 3 ROP in Zone II. A clear ridge is seen at the border of the vascularised and avascular retina. There is extraretinal fibrovascular proliferation extending into the vitreous from the ridge. The posterior aspect of the ridge is irregular. On this image, the ROP is seen to extend for at least 4 clock hours from 1 o'clock to 5 o'clock. There is evidence of pre-plus disease. There is no evidence of AP-ROP. Treatment is not indicated. Follow-up is recommended in one week.

4





This image demonstrates Stage 3 ROP in Zone II. On this image, the ROP is seen to extend for at least 4 clock hours from 7 o'clock to 11 o'clock.

There is marginally increased tortuosity of vessels, indicating the presence of pre-plus disease. There is no evidence of AP-ROP.

Treatment is not indicated.

Follow-up in one week is recommended.

<p>5</p> 	<p>This image demonstrates Stage 3 ROP in Zone I.</p> <p>On this image, the ROP is seen to extend for at least 4 clock hours from 7 o'clock to 11 o'clock.</p> <p>Plus disease is present.</p> <p>There is no evidence of APROP.</p> <p>Treatment is indicated.</p>
<p>6</p> 	<p>This image demonstrates Aggressive Posterior ROP in the posterior pole. Prominent "seafan"-shaped circumferential neovascularisation is present between Zones I and II.</p> <p>AP-ROP is difficult to stage as it does not follow the usual progression.</p> <p>There is marked tortuosity of the vessels.</p> <p>There are vitreous haemorrhages seen in at the junction of the vascular and avascular retina.</p> <p>There is also vitreous haze.</p> <p>The findings are indicative of Aggressive Posterior ROP.</p> <p>Treatment is indicated.</p>
<p>Photo Courtesy: Dr. Pranab Das, Calcutta Medical Research Institute</p> <p>http://www.boostnz.info/ROP/imagereview1.htm</p>	

STEPS INVOLVED IN IMPLEMENTING UNIVERSAL EYE SCREENING IN NEWBORNS INCLUDING ROP

A. Basic Steps

- **Universal Vision Screening** should be done at all delivery point through Doctors & ANMs/Staff Nurses.
- All States and UTs should establish at least one **State level Apex unit for ROP** which would function also as a training unit. This unit should be located at the SNCU/NICU of a Government Institution.
- Instruments like Indirect Ophthalmoscope, dedicated LASER equipment with indirect console should be placed at this unit. RETCAM can be optional.
- Both the screening and management should be done at the SNCU/NICU. At least 2 beds to be reserved for ROP procedure and a dedicated radiant warmer to be earmarked for the same.
- One doctor and one nurse from SNCU/NICU to be assigned and trained for screening & management of ROP.
- Ophthalmologist to be identified either within the Gov. sector or even from any private sector who could visit at least once a week and could be paid for each case as per the norms.
- Help from collaborative centres to be sought in establishing teaching & training units.

B. Service Mapping (Desk Work)

Baseline Service and resource mapping should be done to prioritize ROP services provision in the SNCU units in phased manner.

- **SNCUs in Medical Colleges and District Hospitals:**
 - Assess the number of infants ≤ 2000 gm admitted who survive to discharge so as to prioritize ROP program implementation in SNCUs caring for the largest number at risk in the first instance (Government database)
- **Eye care providers:**
 - Ophthalmologists in Regional Institutes of Ophthalmology, Medical Colleges and District Hospitals and their existing skills/willingness to be trained in a) screening and b) treating ROP
 - Ophthalmologists in the private sector and their competencies in screening and treatment
 - Equipment available for screening and treating ROP
- **District Early Intervention Centers (DEICs)** - location, staffing levels and equipment for eye care (as per the RBSK Guidelines)
- Prioritize a functioning SNCU within the state with adequate load and upgrade it as the nodal center for teaching and training of SNCU staff and district Ophthalmologist.
- Collaborative institutions including Medical College could be used for mentoring such state-wise nodal training center

C. Administrative Arrangements for Implementation at District Level

<p>Formation of a committee at the district level comprising:</p> <ol style="list-style-type: none"> 1. Chief Medical officer 2. Nodal officer RCH 3. Ophthalmologist of the District Hospital 4. Medical Officer of SNCU 5. Nursing Staff of SNCU 6. Optometrist from the DEIC 7. Administrative personnel of the District Hospital 8. Representation from NPCB 9. Representation from Local Ophthalmic association 10. DEIC Manager 	
<p>Ensure: ROP Screening for all preterm in accordance with the guidelines for Screening and management of ROP under RBSK</p> <ol style="list-style-type: none"> a. all preterm infants admitted to SNCU weighing less than or equal to 2000 gm. at birth b. all preterm infants weighing more than 2000 gm. who have received supplemental oxygen or have suffered from sepsis c. if the SNCU Paediatrician has any concern 	<p>Ensure:</p> <ol style="list-style-type: none"> a. The nursing staff line-list all the babies fulfilling the criteria for ROP b. that the pupils are dilated half an hour before the ophthalmologist comes for screening c. SNCU Doctor has counselled and taken the consent from the family d. the screening sets and instruments are sterile and ready e. the optometrist and nurse assist the ophthalmologist in the screening
<p>Ensure:</p> <p>Screening must be done before discharge or by 30 days of life whichever is sooner</p>	<p>Ensure:</p> <ol style="list-style-type: none"> a. That the DEIC Manager and the optometrist have maintained the record b. Counselling and Follow up with the parents
<p>Ensure:</p> <p>That the indirect ophthalmoscope is available along with the 20 D lens</p> <p>Training has been imparted to both the ophthalmologist and optometrist in this aspect</p>	<p>Ensure:</p> <p>Superintendent of the District Hospital to help in the logistics including availability of funds to support this activity</p>
<p>Ensure:</p> <p>Regular weekly visits on the same day of the week at the same time to SNCU Units by the district ophthalmologist or any trained doctor</p> <p>Ensure daily visit to the SNCU by the Optometrist for examining every new born</p>	<p>Ensure:</p> <p>Superintendent of the District Hospital to make this mandatory</p> <p>DEIC Manager to see that the optometrist regularly visits the SNCU</p>

<p>Ensure: Follow-up:</p> <p>1) Every pre-term is followed up till either the retinal vessels become mature or the ROP regresses and the PMA is greater than 42 weeks</p> <p>2) Parents understand the significance of this follow up and if need be urgent treatment / assessment is made possible</p>	<p>Ensure:</p> <p><i>SNCU in charge</i> follows the protocol for new born vision examination and ROP for preterm</p> <p>That the DEIC Manager should maintain monthly records of all such children along with their follow up and ensure that the data is reflected in the SNCU Data Base</p>
--	--

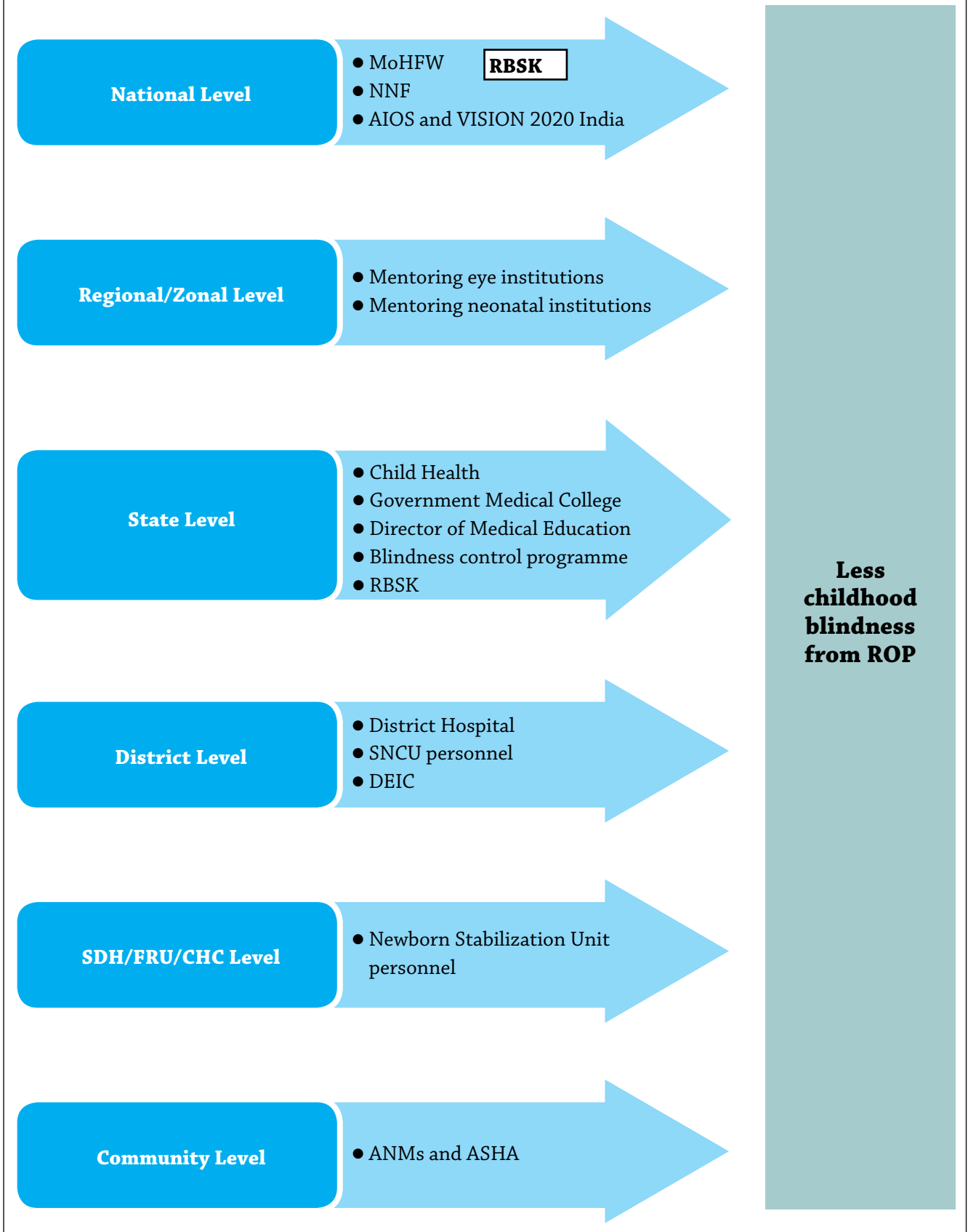
Level	Roles and responsibilities
National	<p>MoHFW</p> <ul style="list-style-type: none"> ● Integrate universal eye screening including ROP screening and treatment services with NPCB and RBSK ● Integrate ROP prevention and screening data fields in the online SNCU and RBSK database ● Integrate ROP service with guidance of National Collaborative Centre for SNCU. ● AIOS and Vision 2020 ● Increase awareness and participation of VR specialist in ROP screening and treatment. ● Making parents aware of the important causes of childhood blindness and its prevention; importance of universal eye screening and ROP screening
Regional	<ul style="list-style-type: none"> ● Centers of Excellence for neonatal care and eye care will provide technical support in capacity building and mentoring. ● Establish pool of trainers for screening and management of ROP ● Identify one Medical College/ Hospital to support 2-3 Nodal SNCUs.
State	<ul style="list-style-type: none"> ● Identify one nodal SNCU for operationalization of ROP and Universal Eye Screening at all the District SNCUs ● Ophthalmology department to train ophthalmologists, PGs and DH ophthalmologist. Pediatrics department to train SNCU staffs and doctors ● Collaborate with State chapters of professional bodies
District	<ul style="list-style-type: none"> ● District coordinator has to report the current statistics to State. ● District coordinator has to provide list of potential trainees. ● DEICs to screen for other visual impairments and refer to pediatric ophthalmologist
Facility# (see below)	<ul style="list-style-type: none"> ● Delivering screening services with appropriate referrals ● Recording and reporting information on screening and treatment ● Arrange long term follow up of all preterm infants at DEIC
Community	<ul style="list-style-type: none"> ● ANMs and ASHA workers generate awareness and promote antenatal steroids and facility based deliveries ● Ensure follow up for screening and long term follow up

Roles and Responsibilities of SNCU staff	
Neonatologist/ Pediatrician	SNCU Nurse for ROP
<ol style="list-style-type: none"> 1. Identify infants to be screened 2. Perform Universal Eye Screening including Red Reflex 3. Document findings of each baby screened 4. Support ophthalmologist during treatment of ROP in SNCU 5. Ensure receiving neonatal unit of infant referred to another neonatal unit are informed of the need for further screening, if required 	<ol style="list-style-type: none"> 1. Keep a diary of the date for screening of all at risk infants from the date of admission and thereafter in coordination with neonatologist 2. Perform Universal Eye Screening 3. Prepare equipment and child for screening 4. Support ophthalmologist during treatment of ROP in the SNCU 5. Ensure findings and management decisions are documented 6. Communicate with and counsel parents about the need for further screening, and when 7. Report the statistics to the district coordinator on a monthly basis 8. Provide ANMs and ASHAs information about the infant which needs follow up
<p>Roles and Responsibilities of DEIC staff:</p> <ul style="list-style-type: none"> ● The optometrist has to daily visit the SNCU ● Examine all children within the SNCU for Vision: including Red reflex, torch light for pupillary examination and visible Eye defects ● Be part of the team along with the SNCU staff to screen ROP for preterm children ● Along with DEIC manager help in follow up and documentation 	

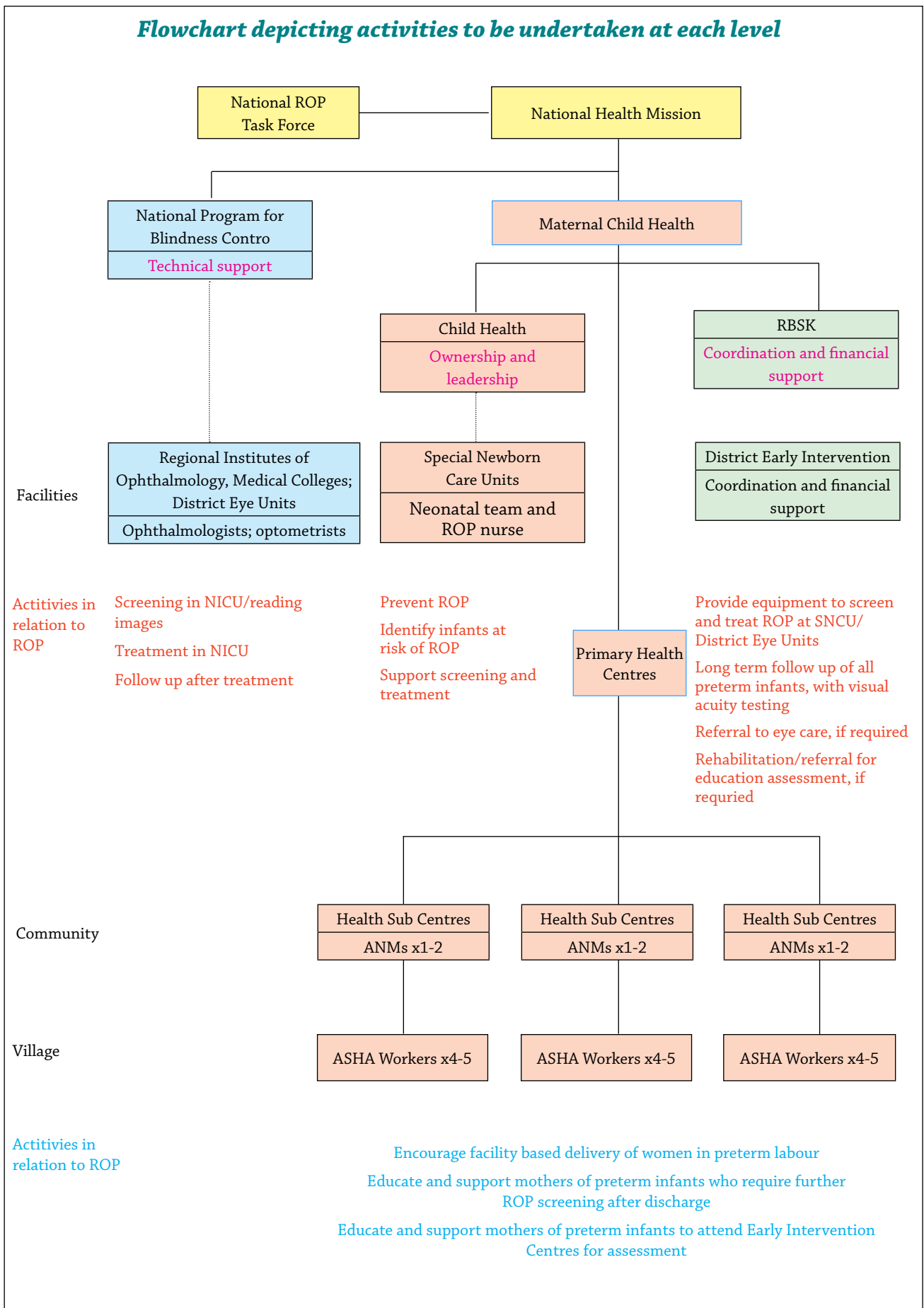
INTEGRATED APPROACH TO UNIVERSAL EYE SCREENING

DEPARTMENT OF NHM CHILD HEALTH	NATIONAL PROGRAM FOR THE CONTROL OF BLINDNESS (NPCB)	RBSK
<p>PREVENTION</p> <ol style="list-style-type: none"> 1. Ensure identification of all preventable causes of childhood blindness 2. Promote facility based delivery of preterm babies 3. Ensure antenatal steroids for mothers likely to deliver preterm 4. Ensure high quality care practices 5. Ensure availability of essential equipment and infrastructure 		<p>PREVENTION</p> <p>Ensure ANMs and ASHAs provide information about screening as a mandate for preterm deliveries</p>
<p>SCREENING</p> <ol style="list-style-type: none"> 1. Set-up screening protocols in all delivery points for universal eye screening in newborns 1. Set-up screening protocols in SNCUs 2. Identify infants to be screened as per guidelines 3. Ensure competent screeners visit on a regular weekly basis and document their findings 	<p>SCREENING</p> <p>Ensure participation of District Hospital ophthalmologists in competency based management of universal eye screening including ROP</p>	<p>SCREENING</p> <p>SNCU neonatologists/ paediatricians ensure all infants admitted are screened for eye disorders including ROP</p>
<p>TREATMENT</p> <p>Coordinate with treating ophthalmologist and provide support during and after laser treatment</p>	<p>TREATMENT</p> <p>Ensure all centres with trained ophthalmologists have equipment for screening and laser treatment</p>	<p>TREATMENT</p> <p>Skilled ophthalmologists conduct laser/surgery according to need</p>
<p>FOLLOW UP</p> <p>Routine follow up of all preterm infant until the age of 2 years</p>	<p>FOLLOW UP</p> <p>Routine follow up of all infants treated for sight threatening ROP</p>	<p>FOLLOW UP</p> <p>Routine follow up of all preterm infant until the age of 7 years for other visually impairing complications</p>

Flow chart: Roles and responsibilities at each level



Flowchart depicting activities to be undertaken at each level



Roles and responsibilities of the neonatology team and ophthalmologist (or technician) in relation to screening for ROP in the SNCU

Roles	Guidelines	Responsibility
Identify infants to be examined/screened	Use national guidelines	Neonatologist
Document date of first examination / screening in medical/nursing records	Use ROP diary	ROP nurse
		Neonatologist
Communicate need for examination/ screening to parents	Verbal explanation and written information	ROP nurse
		Neonatologist
Prepare infants for examination	Use national guidelines	ROP nurse
Assist ophthalmologist/ technician during examination		ROP nurse
Monitor infant during examination/ screening		ROP nurse
Document findings	Medical records	Ophthalmologist
	Nursing records	ROP nurse
Communicate findings to parents		Ophthalmologist
		ROP nurse
Inform parents if further exam is needed and when		Ophthalmologist
		ROP nurse
Document date for next exam in medical/ nursing records	Use ROP diary	Ophthalmologist
	In medical records/discharge summary	ROP nurse
Trace parents / health worker of infants who fail to attend after discharge		ROP nurse

Roles and responsibilities of the neonatology team and ophthalmologist in relation to treatment for ROP

Explain treatment to parents	Verbal explanation, and written information	Ophthalmologist
		Neonatologist
Prepare infant for treatment	Systemic: national guidelines	Neonatologist
	Eye(s): national guidelines	ROP nurse
Monitor infant during treatment		Neonatologist or anaesthetist
Document that treatment given in medical/nursing records		Ophthalmologist
		Neonatologist/ROP nurse
Give parents date for follow up		Ophthalmologist
		ROP nurse
Document date of next exam in medical/nursing records		Ophthalmologist
		ROP nurse
Contact parents if fail to attend for follow up		Ophthalmologist ROP nurse

RETINOPATHY OF PREMATUREITY

WHOM TO SCREEN?

Gestation < 34 weeks or Birth weight < 2000 grams

Any preterm infant with risk factors:

- Cardiorespiratory support
- Prolonged oxygen requirement
- Respiratory distress syndrome
- Chronic lung disease
- Blood transfusion
- Sepsis
- Exchange transfusion
- Intraventricular haemorrhage
- Apnea
- Poor post-natal weight gain

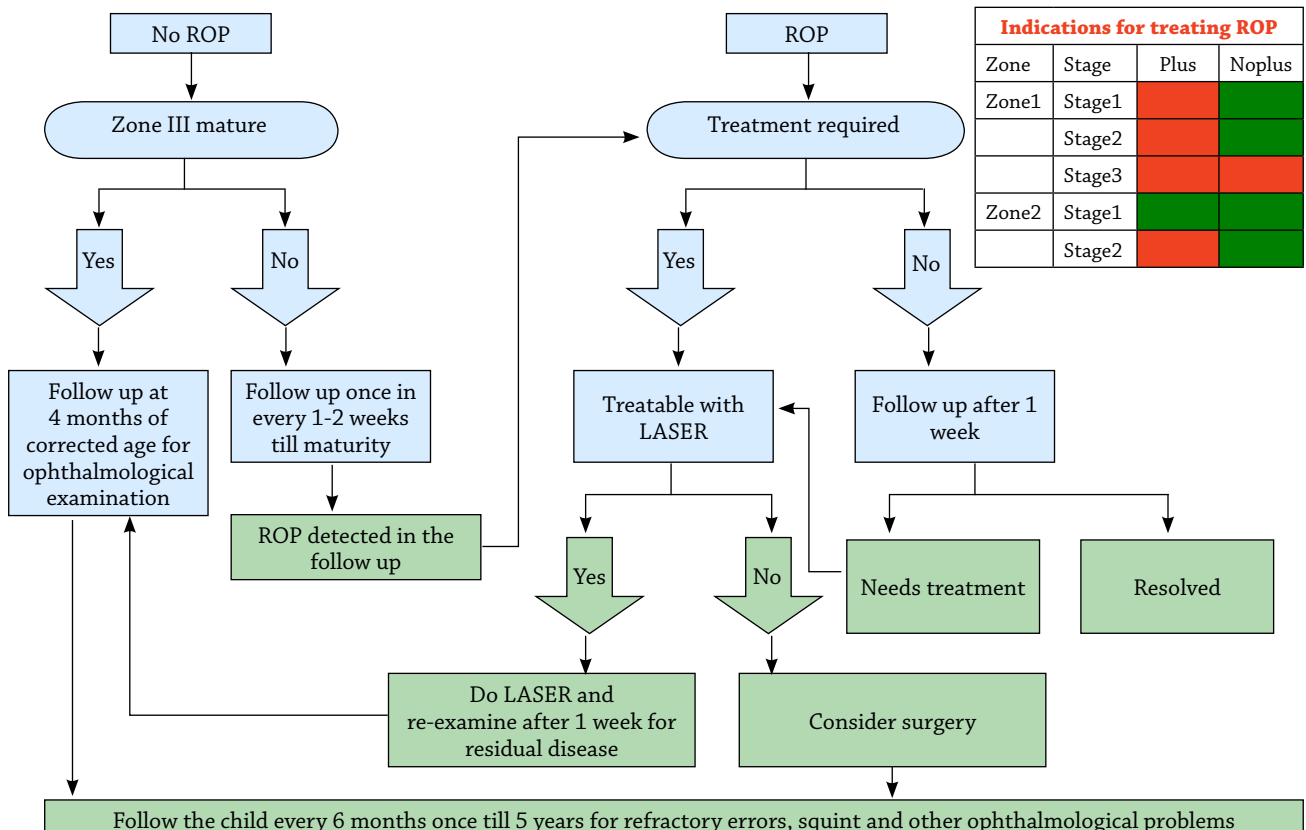
PREVENTIVE FACTORS

- Antenatal steroids
- Restrict use of Oxygen
- If baby on Oxygen target SpO2 between 90-95%
- Use CPAP when required
- Early enteral nutrition (breast milk preferred)
- Aggressive nutrition therapy
- Following aseptic precautions
- Restrictive blood transfusion policy

AGGRAVATING FACTORS

- Small for gestational age
- Uncontrolled Use of Oxygen
- Patent ductus arteriosus
- Sepsis
- Inadequate weight gain
- Prolonged ventilation
- Transfusion of blood products

Initial Screen at 4 Weeks (30 Days) of Birth. Infants with period of gestation less than 28 weeks or weighing less than 1200 gms, first screening to be done at 2-3 weeks after birth.



Follow the child every 6 months once till 5 years for refractory errors, squint and other ophthalmological problems

LIST OF COLLABORATIVE INSTITUTIONS AND TECHNICAL RESOURCE PERSONS TO FACILITATE RBSK FOR ITS INITIATIVES IN SCREENING AND MANAGING CHILDREN WITH VISION IMPAIRMENT INCLUDING ROP:

1. Dr. R. P. Centre, All India Institute of Medical Sciences, New Delhi: Contact person - a) Prof. Dr. Pradeep Sharma, Email: drpsharma57@yahoo.com; b) Prof. Dr. Parijat Chandra, Email: parijatchandra@gmail.com
2. Postgraduate Institute of Medical Education & Research, Chandigarh: Contact person - a) Prof. Dr. Mangat R Dogra, Email: drmangatdogra@gmail.com; b) Prof. Dr. Praveen Kumar, Email: drpkumarpgi@gmail.com
3. L V Prasad Eye Institute, Hyderabad: Contact person - a) Prof. Dr. Gullapalli N Rao b) Dr. Subhadra Jalali, Email: subhadra@lvpei.org c) Dr. Ramesh Kekunnaya, Email: drrk123@gmail.com
4. Sankara Nethralaya (Main Campus), Chennai: Contact person - a) Dr. T S Surendran Email: drtss@snmail.org; b) Dr. Pramod S Bhende, E-Mail: drpb@snmail.org
5. Calcutta Medical Research Institute and Hospital: Contact person - a) Dr. Pranab Das, Email: drpranab2008@gmail.com
6. Narayana Nethralaya, Eye Hospital Bangalore: Contact person - a) Dr. Anand S Vinekar, Email: anandvinekar@yahoo.com
7. Aravind Eye Hospital, Madurai: Contact person - a) Prof. Dr. P. Vijayalakshmi, Chief-Paediatric ophthalmology, Email: p.vijayalakshmi@aravind.org
8. All India Institute of Medical Sciences, New Delhi: Contact person - Prof. Dr. Ashok Deorari, Email : ashokdeorari_56@hotmail.com
9. Institute of Post Graduate Medical Education and Research: Contact person - a) Prof. Dr. Suchandra Mukherjee, Email: drsmukherjee70@gmail.com b) Dr. Pranab Das, Email: drpranab2008@gmail.com
10. Aravind Eye Hospital, Coimbatore: Contact person - Dr. V. Narendran, Email: narendran@cbe.aravind.org
11. Chetana Charitable Trust, Chennai: Contact person - a) Dr. Namita Jacob, Program Director, Email: namitaj@yahoo.com

International Faculty:

- Prof. Dr. Lea Hyvarinen: Paediatric ophthalmologist at University of Dortmund & Univ. of Helsinki. Developed LEA Vision Tests for assessment & screening of children's vision. (lea.hyvarinen@lea-test.fi) & Rex Temple: rtemple@leatest.com
- Prof. Clare Gilbert: Paediatric ophthalmologist and International Eye Health at London School of Hygiene and Tropical Medicine. (Clare.Gilbert@lshtm.ac.uk)



Ministry of Health & Family Welfare
Government of India